

## Case report

# A novel mutation in a patient with familial renal hypouricemia type 2

Kubra Kaynar<sup>a,\*</sup>, Beyhan Güvercin<sup>a</sup>, Mustafa Şahin<sup>b</sup>, Nilay Turan<sup>b</sup>, Ferhat Açıkkyürek<sup>b</sup>

<sup>a</sup> Department of Nephrology, School of Medicine, Karadeniz Technical University, Trabzon, Turkey

<sup>b</sup> Department of Internal Medicine, School of Medicine, Karadeniz Technical University, Trabzon, Turkey

### ARTICLE INFO

#### Article history:

Received 25 June 2021

Accepted 16 July 2021

Available online 16 August 2021

#### Keywords:

Acute kidney injury

Mutation

Uric acid

### ABSTRACT

**Introduction:** Hypouricemia may be caused by disorders leading to decreased UA production, oxidation of UA to allantoin by drugs or increased renal tubular loss of filtered UA, renal hypouricemia (RHUC). RHUC may be resulted from familial or acquired disorders. Familial RHUC cases are classified according to the gene affected as type 1 (SLC22A12 gene) and type 2 (SLC2A9). Clinical importance of RHUC entity is mainly determined by emerging of acute kidney injury (AKI) after strenuous exercise and urolithiasis.

**Case presentation:** Here, we report a case of RHUC with increased fractional excretion of uric acid value of more than 100%, serum uric acid level of nearly zero, and exercise-induced AKI episodes clinically and a new unpublished homozygous (biallelic) mutation of c.1419+2T>G (IVS11+2T>G) in the SLC2A9 gene genetically for the first time to our knowledge.

**Conclusion:** Clinicians should be aware of this rare entity defined as hereditary RHUC in order to provide long term renoprotection by advisements like simple precautions such as avoiding severe exercises.

© 2021 Sociedad Española de Nefrología. Published by Elsevier España, S.L.U. This is an open access article under the CC BY-NC-ND license (<http://creativecommons.org/licenses/by-nc-nd/4.0/>).

## Introduction

Renal hypouricemia (RHUC) is defined as decreased serum uric acid (UA) level (less than 2 mg/dL) due to severe renal uric acid loss with increased fractional uric acid excretion (FEUA).<sup>1</sup> Majority of RHUC patients are asymptomatic and incidentally recognized.<sup>2</sup> Clinical importance of RHUC is mainly determined by emerging of acute kidney injury (AKI) after strenuous

exercise and urolithiasis.<sup>1</sup> Long term renal outcome of these patients and factors affecting long term renal outcome are not known clearly.

Familial RHUC is a rare autosomal recessively transmitted genetic disorder mostly with variable mutations. So the diagnosis of familial RHUC is confirmed by detection of genetic mutations. In emergence of familial RHUC entity, mainly two types of genes with many mutations were considered. Type 1 familial RHUC is caused by the mutations in the urate anion exchanger 1 (URAT1) coding gene named as SLC22A12 gene and type 2 familial RHUC is caused by mutations in the glucose transporter 9 (GLUT9) coding gene named as SLC2A9

\* Corresponding author.

E-mail address: [kkaynar@yahoo.com](mailto:kkaynar@yahoo.com) (K. Kaynar).

<https://doi.org/10.1016/j.nefro.2021.07.006>

0211-6995/© 2021 Sociedad Española de Nefrología. Published by Elsevier España, S.L.U. This is an open access article under the CC BY-NC-ND license (<http://creativecommons.org/licenses/by-nc-nd/4.0/>).

**Table 1 – Clinical and laboratory findings of the patient.**

Parameter	Patient
Age	47
Gender	Male
Complain	Nausea and vomiting after exercise
Family history	Absent
Consanguinity between parents	Present (first degree cousins)
Blood pressure (mmHg)	100/60
Serum uric acid level (mg/dL)	
Basal level/during AKI <sup>a</sup> /last visit	0.1/1.8/0.08
Serum creatinine level (mg/dL)	
Basal level/during AKI/last visit	0.65/6.59/0.72
Glomerular filtration rate (mL/min/1.73 m <sup>2</sup> )	
(CKD-Epi-cr)	116/9/111
Basal level/during AKI/last visit	
Fractional excretion of uric acid (%)	142
Serum glucose level (mg/dL)	99
Urine glucose excretion (mg/day)	12
Serum phosphorus level (mg/dL)	3.1
Fractional excretion of phosphorus (%)	20
Urine protein excretion (mg/day)	
During AKI/last visit	132/116
Human Immunodeficiency virus	Negative
Drug history	None
Urolithiasis	Not detected by computed tomography
Comorbid diseases	None
Diagnosis based on	Clinical criteria and genetic analysis
Genetic analysis	homozygous mutation of c.1419+2T>G (IVS11+2T>G) in the SLC2A9 gene.

<sup>a</sup> AKI, acute kidney injury.

(located on 4p16.1). The mutations in these genes lead to defective renal proximal tubular uric acid transport through both decreased reabsorption and increased secretion.<sup>2</sup>

Here, we report a case of familial RHUC with exercise induced AKI clinically and a new unpublished homozygous (biallelic) mutation of c.1419+2T>G (IVS11+2T>G) in the SLC2A9 gene genetically for the first time to our knowledge.

## Case presentation

A 47-year-old male patient applied to our clinic with nausea, vomiting and history of two recurrent episodes of acute kidney injury (AKI) after exercise (12 h of working at garden) during the years between 2014 and 2017. His family history revealed that parents were cousins of first degree. There was no history of medication (such as probenecid, sulfinpyrazon, enalapril, losartan, amlodipine, fenofibrate, atorvastatin, trimetoprim-sulfamathoxazole).

His blood pressure was 100/60 mmHg. Body mass index was 31 kg/m<sup>2</sup>. No other pathology was detected by physical examination. Biochemically his serum creatinine level was 6.59 mg/dL and serum uric acid level was 1.8 mg/dL. Ultrasonography revealed normal kidneys in size and echogenicity. Serum uric acid levels of the patient was noticed to be lower than normal (1.8 mg/dL) although estimated glomerular filtration rate (eGFR) using Chronic Kidney Disease Epidemiology Collaboration (CKD-EPI creatinine) was severely decreased (9 mL/min/1.73 m<sup>2</sup>) due to acute kidney injury. Fractional uric acid (urate) excretion (FEUA) calculated via 24-hour urine

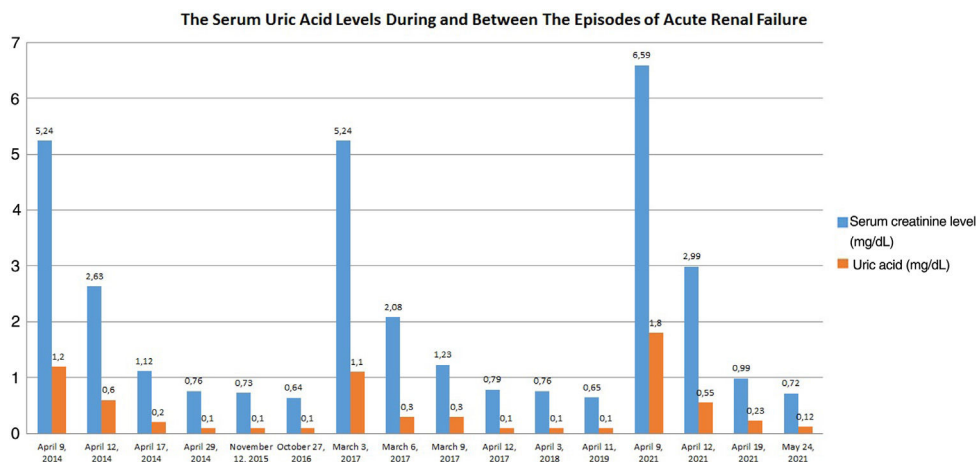
collection was found to be inappropriately higher (Table 1). FEUA was calculated as 142% by the formula as follows:  $FEUA = 100 \times (\text{Urine urate} \times \text{Plasma Cr}) / (\text{Plasma urate} \times \text{Urine Cr})$ .<sup>3</sup>

Clinical diagnostic criteria of RHUC was defined as serum uric acid levels less than 2 mg/dL and in the mean time increased FEUA > 11%.<sup>3</sup> Confirmatory genetic analysis had been performed and identified a novel homozygous (biallelic) mutation of c.1419+2T>G (IVS11+2T>G) in the SLC2A9 gene. Computed tomography did not detect renal or ureteral nephrolithiasis. Serum phosphorus levels were normal (3.1 mg/dL). Glycosuria was not detected in complete urine analysis and the glucose level in a 24-h urine sample was found to be 12 mg/day (normal, <0.5 g/day).<sup>4</sup>

After bed rest and fluid resuscitation had been given, serum creatinine level of the patient decreased to 0.72 mg/dL and serum uric acid level was undetectable (Fig. 1). Restriction of heavy exercise was repeatedly advised and the patient was discharged.

## Discussion

Hypouricemia may be caused by hereditary (xanthine oxidase deficiency) or acquired (inhibitor of xanthine oxidase) disorders leading to decreased UA production, oxidation of UA to allantoin by drugs (rasburicase) or increased renal tubular loss of filtered UA.<sup>5</sup> RHUC was first reported in Japan in 1975 and mostly seen among Japanese with a prevalence of 0.3%.<sup>6</sup> Although most of these patients are Asians, cases also have been reported from many countries including Spain.<sup>7</sup> A few RHUC



**Fig. 1 – The serum uric acid levels of the patient during and between the episodes of acute renal failure.**

cases were published in national journals of Turkey, but large scale epidemiological survey searching RHUC prevalence is absent.<sup>8</sup>

RHUC may be caused by familial or acquired disorders [such as Fanconi syndrome (cystinosis, multiple myeloma), volume expansion, acquired immunodeficiency syndrome, intracranial diseases, pregnancy, uricosuric drugs (probenecid, trimetoprim-sulfamathoxazole, etc.), amanita phalloides poisoning].<sup>5</sup> Clinically, absence of renal glycosuria, and normal serum phosphorus levels without renal phosphorus loss made us ruled out RHUC due to Fanconi syndrome. Patients with low serum uric acids due to increased renal excretion should be screened for uricosuric drug history such as probenecid, trimethoprim-sulfamethoxazole, high-dose salicylate, fenofibrate, losartan. Intake of these drugs was absent in our patient's history. So, these acquired disorders could not have been identified in our patient.

Two types of genetic defects in tubular UA transporters were described for familial RHUC cases. Mutations either on chromosome 11q13 coding URAT1, or chromosome 4p15.3-p16 coding GLUT9 were described.<sup>5,7</sup> Homozygous mutations for URAT1 mostly lead to serum uric acid levels of less than 1 mg/dL, FEUA of 40–90% in affected patients and more often nephrolithiasis episodes than general population. On the contrary less common exercise-induced AKI cases were seen in cases with the genetic mutations in the gene coding URAT1.<sup>5</sup> While patients with homozygous mutations in the gene coding GLUT9 present with serum uric acid levels close to zero with FEUA of 100% and high incidence of exercise-induced AKI and renal calculi.<sup>5</sup> Serum uric acid levels of our patient were 0.1–0.3 mg/dL and FEUA level was 142%. He had recurrent episodes of AKI with exercise without renal calculi. Based on these results, our patient's findings were found to be consistent with the phenotypic features of mutations in the gene coding GLUT9. The presence of increased FEUA value of more than 100%, serum UA level of nearly zero, and exercise-induced AKI episodes makes us think that this novel mutation (c.1419+2T>G (IVS11+2T>G) in GLUT9 coding gene (SLC2A9) of our case is pathogenic. Although many mutations regarding GLUT9 coding gene (SLC2A9) had been reported, most of them

were found as benign, at the present time, only 12 pathogenic mutations were identified as far as we know.<sup>9</sup>

Even though definition of RHUC comprises serum uric acid levels <2 mg/dL with FEUA >10%, it might be difficult to notice RHUC cases based on this criteria when their renal functions deteriorated with low GFR due to repetitive exercise induced AKI episodes.<sup>10</sup> Long term renal and patient survival of these patients are not known clearly. Clinicians should be aware of this rare entity defined as hereditary RHUC in order to provide long term renoprotection by advisements like simple precautions such as avoiding severe exercises.

In conclusion, prevalences of renal hypouricemia among each countries and implications of genetical mutations on clinical course, long term renal and patient prognosis should be searched thoroughly in order to diagnose and treat appropriately affected individuals before irreversible renal injuries occur.

### Authors' contributions

All authors have read and agreed to the final manuscript. Kubra Kaynar participated in conception, design, interpretation of data of the patient as well as drafting the article and revising it; Beyhan Güvercin contributed in design, interpretation of data of the patient, drafting the article. Mustafa Şahin: reviewed the literature and participated in writing the manuscript. Nilay Turan collected the patient's data, reviewed the literature, Ferhat Açıkyürek collected the patient's data.

### Informed consent

Written informed consent for publication of this case report was taken from the patient.

### Compliance with ethical standards

Informed consent was obtained from the patient.

---

## Conflicts of interest

All of the authors declare no conflict of interests. No fund was taken.

---

## REFERENCES

1. Zhou Z, Ma L, Zhou J, Song Z, Zhang J, Wang K, et al. Renal hypouricemia caused by novel compound heterozygous mutations in the SLC22A12 gene: a case report with literature review. *BMC Med Genet.* 2018;19:142, <http://dx.doi.org/10.1186/s12881-018-0595-8>.
2. Wang C, Wang J, Liu S, Liang X, Song Y, Feng L, et al. Idiopathic renal hypouricemia: a case report and literature review. *Mol Med Rep.* 2019;20:5118–24, <http://dx.doi.org/10.3892/mmr.2019.10726>.
3. Steinhauslin F, Burnier M, Magnin JL, Munafò A, Buclin T, Diezi J, et al. Fractional excretion of trace lithium and uric acid in acute renal failure. *J Am Soc Nephrol.* 1994;4:1429–37.
4. Gerich JE. Role of the kidney in normal glucose homeostasis and in the hyperglycemia of diabetes mellitus: therapeutic implications. *Diabet Med.* 2010;27:136–42.
5. Mount DB. Hypouricemia: causes and clinical significance. 2021 May. UpToDate.com. Available from: <https://www.uptodate.com/contents/hypouricemia-causes-and-clinical-significance> [accessed 12.06.21].
6. Nkayama A, Matsuo H, Ohtahara A, Ogino K, Hakoda M, Hamada T, et al. *Clinical Practice guideline for renal hypouricemia (1st edition)*. *Hum Cell.* 2019;32:83–7.
7. Claverie-Martin F, Trujillo-Suarez J, Gonzalez-Acosta H, Aparicio C, Justa Roldan ML, Stiburkova B, et al. URAT1 and GLUT9 mutations in Spanish patients with renal hypouricemia. *Clin Chim Acta.* 2018;481:83–9, <http://dx.doi.org/10.1016/j.cca.2018.02.030>.
8. Bardak S, Turgutalp K, Kiykım A. Exercise-induced acute kidney injury: a case of renal hypouricemia. *Turk Nephrol Dial Transplant.* 2015;24:217–9, <http://dx.doi.org/10.5262/tndt.2015.1002.14>.
9. Vernon JV. OMIM.org: Online Mendelian Inheritance in Man (OMIM®), an online catalog of human genes and genetic disorders. Available from: <https://mirror.omim.org/entry/606142?search=SLC2A9&highlight=slc2a9> [updated 18.09.20].
10. Yan MT, Cheng CJ, Chen JS, Lin SH. The case: a young man with acute kidney injury after exercise. The diagnosis: exercise induced acute kidney injury in hereditary renal hypouricemia. *Kidney Int.* 2010;77:935–6, <http://dx.doi.org/10.1038/ki.2009.563>.