

3. Johnston O, Rose CL, Gill JS, Gill JS. Risks and benefits of preemptive second kidney transplantation. *Transplantation* [Internet]. 2013;95:705-10, <http://dx.doi.org/10.1097/TP.0b013e3938f1827> [consultado 10 Feb 2021]. Disponible en: <https://journals.lww.com/00007890-201303150-00010>.
4. Girerd S, Girerd N, Duarte K, Giral M, Legendre C, Mourad G, et al. Preemptive second kidney transplantation is associated with better graft survival compared with non-preemptive second transplantation: a multicenter French 2000-2014 cohort study. *Transpl Int* [Internet]. 2018;31:408-23, <http://dx.doi.org/10.1111/tri.13105> [consultado 10 Feb 2021]. Disponible en: <https://pubmed.ncbi.nlm.nih.gov/29210106/>.
5. Florit EA, Bennis S, Rodriguez E, Revuelta I, de Sousa E, Esforzado N, et al. Pre-emptive retransplantation in patients with chronic kidney graft failure. *Transplant Proc* [Internet]. 2015;47:2351-3 [consultado 10 Feb 2021]. Disponible en: <https://pubmed.ncbi.nlm.nih.gov/26518924/>.
6. Arnol M, Prather JC, Mittalhenkle A, Barry JM, Norman DJ. Long-term kidney regraft survival from deceased donors: Risk factors and outcomes in a single center. *Transplantation* [Internet]. 2008;86:1084-9 [consultado 10 Feb 2021]. Disponible en: <https://pubmed.ncbi.nlm.nih.gov/18946346/>.
7. Augustine JJ, Woodside KJ, Padiyar A, Sanchez EQ, Hricik DE, Schulak JA. Independent of nephrectomy, weaning immunosuppression leads to late sensitization after kidney transplant failure. *Transplantation* [Internet]. 2012 Oct 15;94:738-43, <http://dx.doi.org/10.1097/TP.0b013e3182612921> [consultado 10 Feb 2021]. Disponible en: <https://pubmed.ncbi.nlm.nih.gov/22955228/>.
8. Milton CA, Russ GR, McDonald SP. Pre-emptive renal transplantation from living donors in Australia: Effect on allograft and patient survival. *Nephrology* [Internet]. 2008;13:535-40, <http://dx.doi.org/10.1111/j.1440-1797.2008.01011.x> [consultado 10 Feb 2021]. Disponible en: <https://pubmed.ncbi.nlm.nih.gov/19138208/>.
9. Altieri P, Sau G, Cao R, Barracca A, Menneas A, Micchittu B, et al. Immunosuppressive treatment in dialysis patients. *Nephrol Dial Transplant* [Internet]. 2002;17 Suppl 8:2-9, <http://dx.doi.org/10.1093/ndt/17.suppl.8.2> [consultado 10 Feb 2021]. Disponible en: <https://pubmed.ncbi.nlm.nih.gov/12147770/>.
10. Akman B, Özdemir N, Sezer S, Miçozkadioğlu H, Haberal M. Depression levels before and after renal transplantation. *Transplant Proc*. 2004;36:111-3, <http://dx.doi.org/10.1016/j.transproceed.2003.11.021>.

Antonio Franco Esteve^a, Patricio Mas Serrano^{b,*},
Noelia Balibrea Lara^a
e Cristina Gilaber Brotons^a

^a Servicio de Nefrología, Hospital General Universitario de Alicante, Alicante, España

^b Servicio de Farmacia Hospitalaria, Hospital General Universitario de Alicante, Alicante, España

* Autor para correspondencia.

Correo electrónico: patricio.mas.serrano@gmail.com
(P. Mas Serrano).

<https://doi.org/10.1016/j.nefro.2021.05.001>
0211-6995/© 2021 Sociedad Española de Nefrología. Publicado por Elsevier España, S.L.U. Este es un artículo Open Access bajo la licencia CC BY-NC-ND (<http://creativecommons.org/licenses/by-nc-nd/4.0/>).

Pauci-immune necrotizing glomerulonephritis in a patient with ankylosing spondylitis

Glomerulonefritis necrotizante paucimmune en un paciente con espondilitis anquilosante

Dear Editor:

Ankylosing spondylitis (AS) is an autoimmune disease that emerged from the interaction of genetic tendency and environmental risk factors.¹ Patients with AS are mostly diagnosed at the end of their third decade of life after approximately 10 years of insidious course.¹ Membranous glomerulopathy secondary to etanercept therapy, immunoglobulin A (Ig A) nephropathy, and renal amyloidosis were reported as kidney diseases associated with AS.²⁻⁴ Anti-neutrophil cytoplasmic antibody (ANCA)-negative pauci-immune necrotizing glomerulonephritis (PING) is also one of the auto-immune diseases.⁵ The association of PING with AS has not been reported. Herein, we report for the first time the development

of ANCA-negative PING accompanied by pulmonary hemorrhage in a patient with AS.

A 39-year-old male patient was diagnosed as having AS on the basis of bilateral grade 2 sacroileitis (Fig. 1) and inflammatory low back pain that had woken him up at nights for 1 year.⁶ He had been treated with sulfasalazine 1g twice daily and acetaminophen 120 mg/d for 1 year, and methotrexate 15 mg once weekly, methylprednisolone 32 mg/d and colchicine 0.5 mg/d for 2 months in another hospital. Some of the patient's symptoms including swelling and pain of the fingers (dactylitis), and buttocks pain, did not resolve with this management. After the first year of follow-up, a skin lesion biopsy was performed for the leukocytoclastic vasculitis that appeared on his left lower leg. By that time his serum creatinine levels had increased to 4.0 mg/dL from the basal levels of

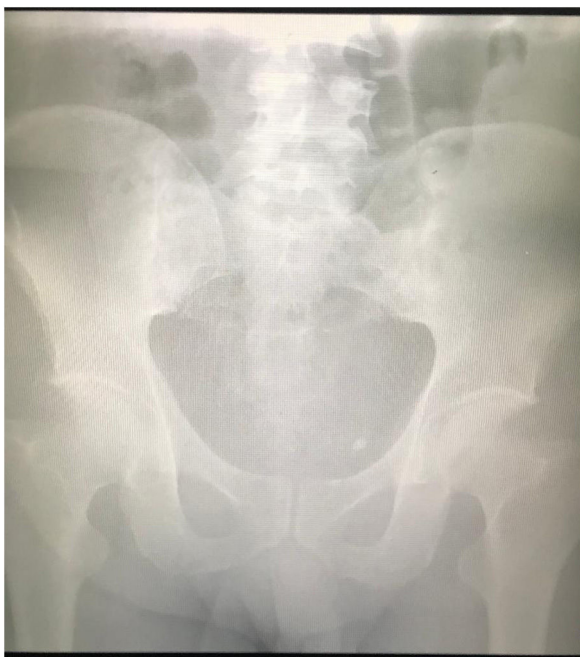


Fig. 1 – Plain (anteroposterior oblique) radiograph of the sacroiliac joint, showing ankylosis, pseudo-widening, and subchondral sclerosis in the right sacroiliac joint (grade 3 sacroiliitis) and subchondral sclerosis pseudo-widening in the left sacroiliac joint (grade 2 sacroiliitis).

0.77 mg/dL in a period of 1 month. He was hospitalized at our department because of the rapid increase in his serum creatinine level and nephrotic range proteinuria (3.9 g/d) with urinary dysmorphic erythrocytes. His serum complement 3 (C3) and 4 (C4) levels were normal (0.94 g/L; normal range, 0.9–1.8; and 0.2 g/L; normal range, 0.1–0.4, respectively), and no antinuclear antibody, anti-double-stranded deoxyribonucleic acid antibody, ANCA, anti-SS-A, anti-Smith (anti-Sm), anti-histone, and anti-nucleosome antibodies were found. Renal biopsy revealed PING, as evidenced by 8% of glomeruli having cellular crescents without immune deposition, 26% of glomeruli having fibrinoid necrosis, fibrosis, and edema in 80% of the interstitium, and subintimal fibrosis in middle-sized vessels (Fig. 2). As soon as the renal biopsy results were released, the patient received pulse (high-dose intravenous [i.v.]) methylprednisone 12.5 mg/kg/d for 3 days.⁷ The rest of the previous medications were stopped. Meanwhile, oliguria, uremic symptoms with hypervolemia, and hemoptysis due to pulmonary hemorrhage developed, and hemodialysis and plasma exchange with albumin replacement were initiated via temporary jugular venous catheter. Subsequently, daily oral methylprednisone 1 mg/kg/d with three doses of i.v. cyclophosphamide 0.5 g/m² every 2 weeks were administered to the patient. However, pulmonary hemorrhage relapsed 4 weeks after initiation of the treatment, so rituximab (i.v. 375 mg/m²) four times weekly were prescribed to the patient. Renal recovery without the need for hemodialysis was observed nearly 2 months after the start of cyclophosphamide treatment and on the third week of rituximab therapy. Azathioprine, methylprednisolone, spironolactone,

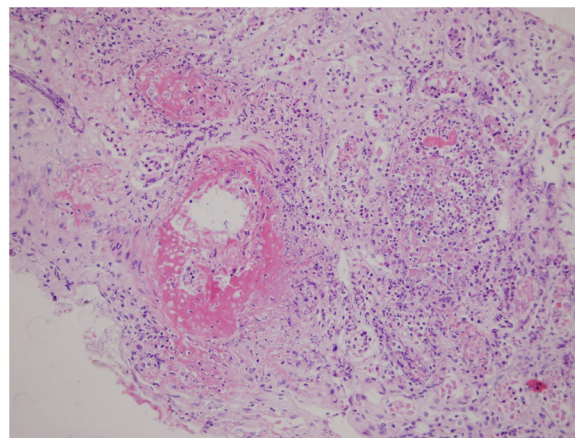


Fig. 2 – Renal biopsy showing diffuse tubulointerstitial inflammation and extensive necrosis destructing the normal structure of the tubuli and glomeruli on light microscopy (hematoxylin–eosin staining, original magnification 200x).

nifedipine, nebivolol, furosemide, pantoprazole, and calcitriol with calcium carbonate were prescribed. The patient is currently followed up in the nephrology outpatient clinic (without dialysis and pulmonary hemorrhage), with a serum creatinine level of 1.7 mg/dL, serum albumin level of 3.6 g/dL, and proteinuria of 1 g/d.

One of the well-known etiologies of rapidly progressive glomerulonephritis is PING. ANCA plays a major role in the pathogenesis of PING. However, 10% of PING cases have been reported to occur without ANCA, similar to our case.⁸ The activation mechanism of the neutrophils that are the primary responsible immune cells in the development of ANCA-negative PING has not been clarified yet.⁹ More severe complement and neutrophil activation and thus greater renal damage were found in ANCA-negative PING cases than in ANCA-positive ones.⁹ The main pathogenetic mechanism of AS is impaired regulation of interleukin-17 production and genetic mutations involving antigen presentation.¹ As knowledge is lacking about the common pathogenic mechanism that leads to both PING and AS, this coexistence may be coincidental. In spite of the worse renal prognosis of patients with ANCA-negative PING, our patient recovered after 2 months of dialysis-dependent renal failure. Renal involvement was reported to be found in 21.7% of cases with AS.¹⁰ The renal pathologies (tubulointerstitial nephritis, IgA nephropathy, nonsteroidal anti-inflammatory drug-induced nephropathy, and amyloidosis) associated with AS were not found in our case. The renal pathology of the present case was PING. This case is important because of the rarity of cases with PING without ANCA, and the present case is the first to show the association of PING with AS.

Funding

No funding was obtained for this article

Inform consent

Written informed consent for publication of this case report was obtained from the patient

Conflict of interest

The authors declare no conflict of interest regarding the publication of this article.

BIBLIOGRAFÍA

- Ranganathan V, Gracey E, Brown MA, Inman RD, Haroon N. Pathogenesis of ankylosing spondylitis – recent advances and future directions. *Nat Rev Rheumatol*. 2017;13:359–67, <http://dx.doi.org/10.1038/nrrheum.2017.56>.
 - Enginar AU, Kacar C. Neutrophil-lymphocyte and platelet-lymphocyte rate and their seasonal differences in ankylosing spondylitis and rheumatoid arthritis patients using anti-TNF medication. *Bratisl Lek Listy*. 2019;120:586–92, <http://dx.doi.org/10.4149/BLL.2019.096>.
 - Barbouch S, Hajji M, Jaziri F, Aoudia R, Fellah E, Hedri H, et al. Renal amyloidosis in ankylosing spondylitis: a monocentric study and review of literature. *Saudi J Kidney Dis Transpl*. 2018;29:386–91, <http://dx.doi.org/10.4103/1319-2442.229291>.
 - Chen R, Li F, Xie Q, Xue J, Lai L, Liu S, et al. Membranous nephropathy in a patient with ankylosing spondylitis: a case report. *Medicine (Baltimore)*. 2017;96:e8201, <http://dx.doi.org/10.1097/MD.0000000000008201>.
 - Geetha D, Jefferson JA. ANCA-associated vasculitis: core curriculum 2020. *Am J Kidney Dis*. 2020;75:124–37, <http://dx.doi.org/10.1053/j.ajkd.2019.04.031>.
 - Yu DT, Tubergen AV. Diagnosis and differential diagnosis of axial spondyloarthritis (ankylosing spondylitis and nonradiographic axial spondyloarthritis) in adults. Available at: <https://www.uptodate.com/contents/diagnosis-and-differential-diagnosis-of-axial-spondyloarthritis-ankylosing-spondylitis-and-nonradiographic-axial-spondyloarthritis-in-adults> [accessed 29.01.21].
 - Falk RJ, Merkel PA. Granulomatosis with polyangiitis and microscopic polyangiitis: management of disease resistant to initial therapy. Available at: <https://www.uptodate.com/contents/granulomatosis-with-polyangiitis-and-microscopic-polyangiitis-management-of-disease-resistant-to-initial-therapy> [accessed 29.01.21].
 - Fernandes S, Teixeira C, Falcão LP, Costa AC, Raimundo M, Silva S, et al. Anca negative pauci-immune crescentic glomerulonephritis and mixed connective tissue disease: a case study. *J Bras Nefrol*. 2019;42:245–9, <http://dx.doi.org/10.1590/2175-8239-JBN-2019-0003>.
 - Sethi S, Zand L, De Vriese AS, Specks U, Vrana JA, Kanwar S, et al. Complement activation in pauci-immune necrotizing and crescentic glomerulonephritis: results of a proteomic analysis. *Nephrol Dial Transplant*. 2017;32:i139–45, <http://dx.doi.org/10.1093/ndt/gfw299>.
 - Lin L, Zhao L, Huo B, Zheng L, Yu R, Li W, et al. Membranous nephropathy and thymoma in a patient with ankylosing spondylitis: a case report. *Medicine (Baltimore)*. 2020;99:e20111, <http://dx.doi.org/10.1097/MD.00000000000020111>.
- Beyhan Güvercin^a, Kubra Kaynar^{a,*}, Hasibe Bilge Gür^b, Sevdegül Mungan^c, Emre Selim^b, Muammer Cansız^a, Şükrü Ulusoy^a
- ^a Faculty of Medicine, Department of Nephrology, Trabzon 61080, Turkey
^b Faculty of Medicine, Department of Internal Medicine, Trabzon 61080, Turkey
^c Faculty of Medicine, Department of Pathology, Trabzon 61080, Turkey
- * Corresponding author.
 E-mail address: kkaynar@yahoo.com (K. Kaynar).
<https://doi.org/10.1016/j.nefro.2021.01.012>
- 0211-6995/© 2021 Sociedad Española de Nefrología. Published by Elsevier España, S.L.U. This is an open access article under the CC BY-NC-ND license (<http://creativecommons.org/licenses/by-nc-nd/4.0/>).

Subcutaneous tocilizumab in chronic active humoral kidney graft rejection

Tocilizumab subcutáneo en rechazo humoral crónico activo sobre injerto renal

Dear Editor,

Almost 10% of kidney transplants present an episode of humoral rejection during its evolution,¹ which decreases long-term graft survival. There are several published tri-

als about the use of tocilizumab (TCZ) in patients with chronic active humoral rejection as first line therapy and rescue treatment, with good results in graft survival.² The experience thus far has supported intravenous TCZ, so we present a case with administration of subcutaneous TCZ.