

* Autor para correspondencia.
 Correo electrónico: edcovi92@gmail.com
 (E.D. Copado Villagrana).

0211-6995/© 2020 Sociedad Española de Nefrología. Publicado por Elsevier España, S.L.U. Este es un artículo Open Access bajo la licencia CC BY-NC-ND (<http://creativecommons.org/licenses/by-nc-nd/4.0/>).
<https://doi.org/10.1016/j.nefro.2020.08.011>

Cartas al Director

C3 glomerulopathy associated to B-cell chronic lymphocytic leukemia

Glomerulopatía C3 asociada a leucemia linfocítica crónica de células B

Dear Editor,

B-cell chronic lymphocytic leukemia (CLL-B) is the most commonly diagnosed leukemia in adults in Europe.¹

Kidney involvement has been described at diagnosis with an incidence of 7.5%^{2,3} and 16.2% during the course of the disease.⁴ C3 glomerulonephritis (C3GN) is a rare disease characterized by accumulation of complement factors in the glomeruli due to overactivation and abnormal regulation of the alternative pathway of complement. One of the abnormalities commonly associated with this entity is the detection of a monoclonal gammopathy, being CLL one of the hematological diseases less commonly associated with C3GN.⁵

We present a case of a 68-year-old woman with overweight, hypertension and diabetes mellitus. She had non-proliferative diabetic retinopathy and hypertensive heart disease. Six months before she had the diagnosis of CLL-B with no clinical or laboratory criteria for targeted treatment.

She presented with uncontrolled hypertension, anasarca and respiratory acidemia due to type 2 respiratory insufficiency, progressing rapidly to respiratory failure and mechanical ventilation. Biochemical investigation showed worsening anemia and leukocyte count, acute renal injury, hyperkalemia, hyperuricemia and hypoalbuminemia. The

urine sediment had leukocyturia, erythrocyturia and hyaline and granulous casts and 24-h urine protein was 5.6 g. A renal ultrasound only showed discrete loss of cortical-medullary transition.

Pleural involvement by CLL was excluded. Serology studies for hepatitis B, C, VDRL and HIV 1 and 2 were negative. Immunologic studies showed decreased complement C3 levels with normal levels of C4. Anti-Neutrophilic Cytoplasmic Autoantibody (ANCA) were negative, cryoglobulins and anti-PLA2R (ELISA) were normal. Electroimmunoblotting showed two bands with monoclonal characteristics (serum IgM/Lambda and IgG/Kappa and urinary IgG/Lambda type and free lambda light chains).

Renal biopsy with seventeen glomeruli, two of which were globally sclerosed and the rest showed a membranoproliferative pattern (Fig. 1A). Renal tubules had thickened tubular basement membranes, there was interstitial mononuclear infiltration without significant fibrosis and moderate arteriolar hyalinosis. Immunofluorescence study revealed mesangial granular deposits for C3 (++) and C4 (+) and vestigial IgM (Fig. 1B). There was no Congo red staining nor green birefringence on polarized light. Electron microscopy revealed electron dense mesangial deposits (Fig. 1C). There was no evidence for deposits along the capillary walls and there was around 40% of foot process effacement.

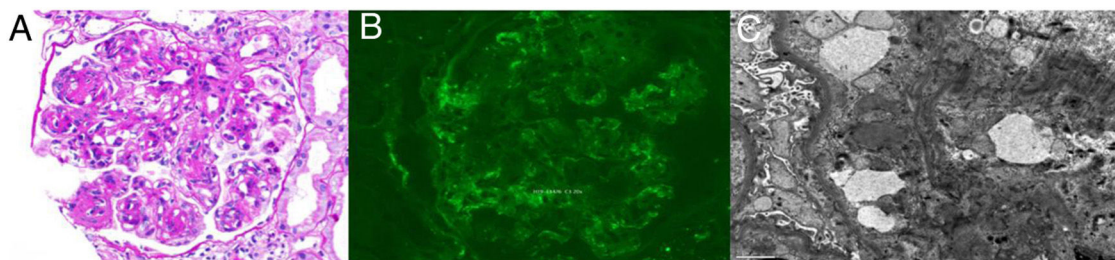


Fig. 1 – (A) Glomerulus showing moderate mesangial widening and thickening of capillary walls, as well as double contours. (Periodic acid-Schiff stain (PAS) stain, 200×), (B) Immunofluorescence microscopy showing small granular deposits of complement (C3), mainly in the glomerula mesangium (×200). (C) Electron microscopy revealing electron dense deposits in the mesangial matrix (×8000).

Table 1 – Biochemical variations along the disease course.

Hematologic and biochemical parameters	Leukocytes ($\times 10^3/\mu\text{L}$)	Lymphocytes ($\times 10^3/\mu\text{L}$)	Hg (g/dL)	Platelet ($\times 10^3/\mu\text{L}$)	sCR (<0.9 mg/dL)	sU (10–50 mg/mL)	Albumin (3.4–4.8 g/dL)	24-h protein (g/day)	Urine protein (mg/g crea)	DHL (U/L)	B2 M (mg/L)	C3 levels (mg/dL)
At diagnosis of CLL	18.6	10.4	11	174	1.3	97	3.1	–	7700	416	4.6	–
At hospital admission	63.9	40.9	7.5	131	1.8	90	2.9	5.6	9200	178	–	58
After treatment	7.6	1.6	11	140	1.2	74	3.8	0.1	3076	182	–	78.2

B2M: beta-2 microglobulin; DHL: lactate deshydrogenase; Hg: hemoglobina; sCr: serum creatinine; sU: serum urea.

A final diagnosis of C3GN was made and renal disease as an underlying immunological phenomenon related to CLL was assumed. A deletion of the TP53 gene was detected and she started treatment with Rituximab and high dose methylprednisolone. After 6 cycles she achieved a complete hematological remission (Table 1) along with stabilization of renal function and marked improvement in the proteinuria.

The first case of kidney disease in CLL was reported in 1957 by Scott et al. in a patient with nephrotic syndrome.⁶ After that, several glomerular diseases have been associated with CLL and depending on the type and stage of the disease, the spectrum of kidney pathology can be particularly wide.⁷ It can occur by diverse mechanisms such as parenchymal infiltration, extrarenal obstruction, tumor lysis syndrome, glomerulopathies, renovascular disease, electrolyte disorders and medication side effects.²

A chronological relationship with a suspected pathophysiological link and a parallel evolution of glomerulopathy and malignancy are suggested of paraneoplastic glomerulopathies.^{8,9} Their pathophysiology is thought to be multifactorial¹⁰ since monoclonal protein secreted by B-cell clone can either be directly involved in the pathogenesis of the lesions, as is seen in fibrillary glomerulopathy, immunotactoid/microtubular glomerulonephritis, AL amyloidosis and type I/II cryoglobulinemia, or indirectly, as in cases of membranoproliferative glomerulonephritis (MPGN) not related to cryoglobulinemia.^{4,11}

MPGN is by far the most common glomerular lesion described, followed by membranous nephropathy, minimal change disease and amyloidosis. Cases of MPGN presenting as C3GN, as the case here discussed, have also been reported.¹² One of the abnormalities commonly associated with C3GN is the detection of a monoclonal immunoglobulins. In this case, impaired regulation of the alternative pathway of complement is caused by monoclonal immunoglobulins and the MPGN pattern on kidney biopsy is the most frequent.¹³

The presence of kidney disease can interfere with treatment strategies and outcomes. Therapy is only required for patients with active or symptomatic disease, or with advanced Binet or Rai stages.¹⁴

Renal prognosis of C3GN remains poor, since 40% of patients progress to end stage renal disease 8–10 years after diagnosis and treatment is not well established.¹⁵

In conclusion, kidney involvement in patients with CLL could be more frequent than previously thought. Since it may present with a variety of pathology patterns and only a few of them predictable on clinical basis, kidney biopsy is essential. C3GN is rarely seen and renal prognosis as well as response to therapy is unknown. The report of these cases is of major role for better understanding the pathophysiology of this disease and in order to improve treatment and prognosis offered to this rare group of patients.

BIBLIOGRAFÍA

1. [Weltgesundheitsorganisation](#). In: Swerdlow SH, Campo E, Harris NL, Jaffe ES, Pileri SA, Stein H, et al., editors. [WHO classification of tumours of haematopoietic and lymphoid tissues](#). Revised 4th ed. Lyon: International Agency for

- Research on Cancer; 2017, 585 p. (World Health Organization classification of tumours).
2. Wanchoo R, Bernabe Ramirez C, Barrientos J, Jhaveri KD. Renal involvement in chronic lymphocytic leukemia. *Clin Kidney J.* 2018;11:670–80.
 3. Strati P, Shanafelt TD. Monoclonal B-cell lymphocytosis and early-stage chronic lymphocytic leukemia: diagnosis, natural history, and risk stratification. *Blood.* 2015;126:454–62.
 4. Strati P, Nasr SH, Leung N, Hanson CA, Chaffee KG, Schwager SM, et al. Renal complications in chronic lymphocytic leukemia and monoclonal B-cell lymphocytosis: the Mayo Clinic experience. *Haematologica.* 2015;100:1180–8.
 5. Ravindran A, Fervenza FC, Smith RJH, Sethi S. C3 glomerulopathy associated with monoclonal Ig is a distinct subtype. *Kidney Int.* 2018;94:178–86.
 6. Scott R. Leukæmia. *Lancet.* 1957;269:1162–7.
 7. Poitou-Verkinder A-L, Francois A, Drieux F, Lepretre S, Legallier B, Moulin B, et al. The spectrum of kidney pathology in B-cell chronic lymphocytic leukemia/small lymphocytic lymphoma: a 25-year multicenter experience. *PLOS ONE.* 2015;10:e0119156.
 8. Cambier J-F, Ronco P. Onco-nephrology: glomerular diseases with cancer. *Clin J Am Soc Nephrol.* 2012;7:1701–12.
 9. Mallouk A, Pham P-TT, Pham P-CT. Concurrent FSGS and Hodgkin's lymphoma: case report and literature review on the link between nephrotic glomerulopathies and hematological malignancies. *Clin Exp Nephrol.* 2006;10:284.
 10. Luciano RL, Brewster UC. Kidney involvement in leukemia and lymphoma. *Adv Chronic Kidney Dis.* 2014;21:27–35.
 11. Seney FD, Federgreen WR, Stein H, Kashgarian M. A review of nephrotic syndrome associated with chronic lymphocytic leukemia. *Arch Intern Med.* 1986;146:137–41.
 12. Chauvet S, Frémeaux-Bacchi V, Petitprez F, Karras A, Daniel L, Burtsey S, et al. Treatment of B-cell disorder improves renal outcome of patients with monoclonal gammopathy-associated C3 glomerulopathy. *Blood.* 2017;129:1437–47.
 13. Ravindran A, Fervenza FC, Smith RJH, Sethi S. C3 glomerulopathy associated with monoclonal Ig is a distinct subtype. *Kidney Int.* 2018;94:178–86. *Kidney Int.* 2018;94:1025.
 14. Hallek M. Chronic lymphocytic leukemia: 2020 update on diagnosis, risk stratification and treatment. *Am J Hematol.* 2019;94:1266–87.
 15. Servais A, Noël L-H, Roumenina LT, Le Quintrec M, Ngo S, Dragon-Durey M-A, et al. Acquired and genetic complement abnormalities play a critical role in dense deposit disease and other C3 glomerulopathies. *Kidney Int.* 2012;82:454–64.
- Filipa Silva ^{a,*}, Joana Tavares ^a, Rita Pinho Peixeiro ^b, João Oliveira ^a, Diana Fernandes ^c, Ana Castro ^a, Sofia Santos ^a, Rita Coutinho ^b, Cristina Freitas ^a, Josefina Santos ^a, João Pedro Pimentel ^a, Jorge Coutinho ^b, António Cabrita ^a
- ^a Nephrology Department, Centro Hospitalar e Universitário do Porto, Portugal
^b Hematology Department, Centro Hospitalar e Universitário do Porto, Portugal
^c Internal Medicine Department, Unidade Local de Saúde do Nordeste, Portugal
- * Corresponding author.
 E-mail address: filipasofiasantossilva@gmail.com (F. Silva).

0211-6995/© 2020 Sociedad Española de Nefrología. Published by Elsevier España, S.L.U. This is an open access article under the CC BY-NC-ND license (<http://creativecommons.org/licenses/by-nc-nd/4.0/>).
<https://doi.org/10.1016/j.nefro.2020.08.010>

Cartas al Director

Acute interstitial nephritis in a patient with chronic idiopathic urticaria

Nefritis intersticial aguda en un paciente con urticaria crónica idiopática

Dear Editor,

Acute interstitial nephritis (AIN) which is characterized as inflammation and oedema around renal tubuli mostly due to hypersensitivity to drugs, has been reported to be underlying aetiology among 5–27% of acute kidney injury cases in hospitalized patients.¹ Chronic idiopathic urticaria (CIU), is an intrinsic immunological abnormality independent of external causes without a triggering stimulus like stress, physical factor, drug and food. It usually affects females with a prevalence of 1% and mostly begins at the age of 30–50 years.² Diagno-

sis mostly depend on chronic recurrent itching persisting at least six weeks with exclusion of diseases like infections, malignities, auto-immune and auto-inflammatory diseases.^{2,3} Treatment is needed for cumbersome symptom of pruritis and life-threatening medical emergency of angioedema. Omalizumab, which is recombinant humanized monoclonal antibody for immunoglobulin (Ig) E is advised for treatment of CIU as the third or fourth line of therapy after histamine receptor type 1 (H₁) antihistamines and leukotriene receptor antagonists are unsuccessful.^{3,4}

A 53-year-old female patient with diabetes mellitus, hysterectomy and CIU had symptoms of nausea and fatigue. In