

Review

Kidney disease associated with androgenic–anabolic steroids and vitamin supplements abuse: Be aware!

Sérgio Luiz Arruda Parente Filho^a, Pedro Eduardo Andrade de Carvalho Gomes^a,
Guilherme Aguiar Forte^a, Laio Ladislau Lopes Lima^a, Geraldo Bezerra da Silva Júnior^b,
Gdayllon Cavalcante Meneses^c, Alice Maria Costa Martins^c,
Elizabeth De Francesco Daher^{a,*}

^a Medical Sciences Post-Graduation Program, Department of Internal Medicine, School of Medicine, Federal University of Ceará, Fortaleza, Ceará, Brazil

^b Public Health Post-Graduation Program, School of Medicine, Health Sciences Center, University of Fortaleza, Ceará, Brazil

^c Department of Clinical and Toxicological Analysis, School of Pharmacy, Federal University of Ceará, Fortaleza, Ceará, Brazil

ARTICLE INFO

Article history:

Received 5 March 2019

Accepted 2 June 2019

Keywords:

Acute kidney injury
Androgenic–anabolic steroids
Chronic kidney disease
Hypercalcemia
Vitamin D
Vitamin supplements

Palabras clave:

Lesión renal aguda
Esteroides androgénicos-anabólicos
Enfermedad renal crónica
Hipercalcemia
Vitamina D
Suplementos vitamínicos

ABSTRACT

The excessive chase for beauty standards and the rise of muscle dysmorphia have ultimately led to an increase in androgenic–anabolic steroids (AAS) and intramuscular injections of vitamins A, D and E (ADE) abuse, which is associated with several adverse effects and has become a public health issue. This review of literature discusses kidney injury associated with the use of AAS and ADE, highlighting the mechanisms of acute and chronic renal lesion, such as direct renal toxicity, glomerular hyperfiltration and hypercalcemia. Future perspectives regarding evaluation and early diagnosis of kidney injury in these patients are also discussed.

© 2019 Sociedad Española de Nefrología. Published by Elsevier España, S.L.U. This is an open access article under the CC BY-NC-ND license (<http://creativecommons.org/licenses/by-nc-nd/4.0/>).

Enfermedad renal asociada con esteroides anabólicos androgénicos y abuso de suplementos vitamínicos: ¡tenga cuidado!

RESUMEN

La búsqueda excesiva de los estándares estéticos y el aumento de casos de dismorfia muscular han llevado a un aumento excesivo del consumo de esteroides anabólicos androgénicos (AAS, por sus siglas en inglés) e inyecciones intramusculares de vitaminas A, D y E (ADE), que se asocian con varios efectos adversos y se convierte en un problema de salud pública. Esta revisión de literatura analiza la lesión renal asociada con el uso de AAS y vitaminas ADE, destacando los mecanismos de la lesión renal aguda y crónica, como la toxicidad renal

* Corresponding author.

E-mail addresses: ef.daher@uol.com.br, geraldobezerrajr@unifor.br (E.F. Daher).

<https://doi.org/10.1016/j.nefro.2019.06.003>

0211-6995/© 2019 Sociedad Española de Nefrología. Published by Elsevier España, S.L.U. This is an open access article under the CC BY-NC-ND license (<http://creativecommons.org/licenses/by-nc-nd/4.0/>).

directa, la hiperfiltración glomerular y la hipercalcemia. También se discuten las perspectivas futuras con respecto a la evaluación y el diagnóstico temprano de lesión renal en estos pacientes.

© 2019 Sociedad Española de Nefrología. Publicado por Elsevier España, S.L.U. Este es un artículo Open Access bajo la licencia CC BY-NC-ND (<http://creativecommons.org/licenses/by-nc-nd/4.0/>).

Introduction

The excessive chase for beauty standards has contributed to the rise of a body image disorder, especially in the young male population: muscle dysmorphia, also known as bigorexia, which is characterized by an obsessive preoccupation that the own body is still insufficiently muscular.^{1,2} It is associated with other psychiatric conditions, such as mood disorders and anxiety^{1,3,4} and has ultimately led to an increase in androgenic-anabolic steroids (AAS) and intramuscular injections of oily compounds abuse.^{1,5}

Steroid abuse is not restricted to professional bodybuilders. In fact, amateurs represent the largest share of AAS users.⁶ A recent study estimated that 2.9–4.0 million North Americans aged from 13 to 50 years had already used AAS, 32.5% of which developed dependence.⁷ These statistics reveal AAS dependence as a public health issue, with figures comparable to those of HIV infection and type-1 diabetes mellitus.⁸ In a Brazilian systematic review, the prevalence of AAS abuse was 2.1–31.6% and the highest prevalence was found among physical education professors and students. This finding is extremely alarming, for these individuals often help and guide other people's physical activity.⁹

Simultaneous use of multiple substances commonly impairs evaluation of adverse effects of each one in isolation.⁴ It is well known that AAS impacts several organ systems. Side effects vary from hypogonadism due to suppression of hypothalamus-pituitary-testis endocrine axis to cardiovascular disorders, including dyslipidemia, cardiomyopathies and arrhythmias.^{8,10,11} On the other hand, the abuse of intramuscular oily compounds (generally vitamins for veterinary use) might result in infection at the site of application, deformities, ulcerations, necrosis, embolism, nerve lesion and formation of foreign body granulomas, which isolate the injected material.⁵ Both substances are also associated with renal damage.

This review of literature discusses kidney injury associated with the use of AAS and intramuscular oily compounds, highlighting the mechanisms of renal lesion and future perspectives regarding evaluation and early diagnosis of kidney injury in these patients. It is important to note that the studies describing the adverse effects related to the use of such substances are still scarce, mostly due to ethical issues, poor understanding of the importance of this topic and patient's refusal to reveal their condition to physicians.⁸

Kidney injury associated with intramuscular vitamin supplementation

Veterinary medications for bovines and equines containing vitamins A, D and E in an oily vehicle (known as ADE) do

not enhance muscle hypertrophy, but the substance itself occupies space in the muscle surface or in the subcutaneous tissue, which leads to a result that is only visually similar to hypertrophy.⁵ While doses of ADE for veterinary purposes are, in average, 5 mL every 120 days, in periods of fattening,⁵ Libório et al.¹² reported a patient who used monthly doses of 50 mL for 2 years.

Both acute kidney injury (AKI) and chronic kidney disease (CKD) have been reported.^{12–17} A series of 16 ADE users by Daher et al.,¹⁸ revealed that 13 patients had AKI according to KDIGO,¹⁹ 7 of which were stage III, 2 required dialysis, and one of them progressed to dialysis-dependent end-stage CKD. Other important findings were hypercalcemia ($\text{Ca}^{2+} > 10.5 \text{ mg/dL}$ or 2.62 mmol/L) in 11 patients; high 25-hydroxvitamin D levels ($> 100 \text{ ng/mL}$) in 9; and suppressed serum levels of parathyroid hormone (PTH) $< 10 \text{ pg/mL}$ in 6 (only 7 patients had their PTH assessed). Treatment consisted in controlling calcium levels and complications, mainly with vigorous crystalloid infusion, corticoids and loop diuretics. Following reversal of hypercalcemia, renal function tended to improve. The data are compatible with different reports in literature.^{12–17}

The 25-hydroxvitamin D contained in the intramuscular injections is probably not the only responsible for the clinical picture, since the latent interval between the beginning of ADE use and hospitalization due to the onset of symptoms was 28 months,¹⁸ which is longer than expected. On the other hand, hypercalcemia also develops with cosmetic injections, like paraffin, silicone and polymethyl methacrylate.²⁰ A possible common mechanism is the formation of granulomas, which express the 1- α -hydroxylase enzyme, which catalyzes the conversion of 25-hydroxvitamin D into its active form 1,25-hydroxvitamin D.²¹ This mechanism is corroborated by the decrease in calcium levels with the administration of glucocorticoids, which are effective against hypercalcemia associated with granulomatous diseases.^{22,23}

However, a review by Tachamo et al.,²⁰ analyzing 23 silicone and polymethyl methacrylate users, revealed a mean latent interval of approximately 95 months, which is even longer than that of ADE users. In addition, Tachamo et al.²⁰ found high 1,25-hydroxvitamin D with low or normal 25-hydroxvitamin D levels, while Daher et al.¹⁸ found high levels of both. Therefore, the absorption of the 25-hydroxvitamin D contained in the injections is probably significant and may accelerate the onset of symptoms.

Although rare, hypervitaminosis A secondary to the absorption of the injected vitamin may also contribute to hypercalcemia,²⁴ possibly by increasing bone reabsorption via vitamin A receptors in osteoclasts.^{25–27} However, only one case report assessed vitamin A levels, which were on the upper limit of normality.¹⁷

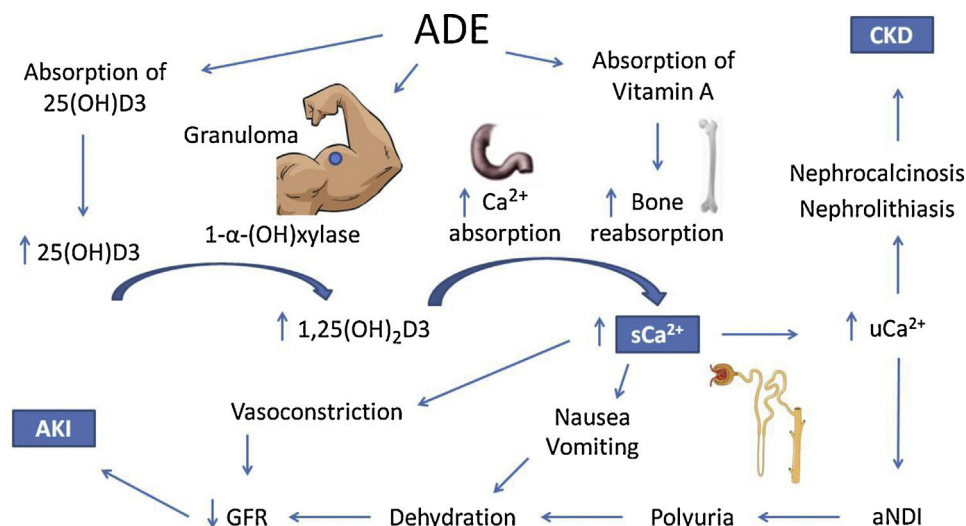


Fig. 1 – Possible mechanisms of hypercalcemia and kidney injury associated with the use of intramuscular vitamins A, D and E. ADE, intramuscular vitamins A, D and E. 25(OH)D3, 25-hydroxivitamin D. 1,25(OH)₂D3, 1, 25-hydroxivitamin D. sCa²⁺, serum calcium. uCa²⁺, urinary calcium. aNDI, acquired nephrogenic diabetes insipidus. CKD, chronic kidney injury. AKI, acute kidney injury.

Adapted from Daher et al.¹⁹

Renal impairment secondary to hypercalcemia may happen through different mechanisms, such as reversible vasoconstriction due to calcium's direct effect on vascular smooth muscle, decreasing renal blood flow and leading to prerenal AKI.²⁸ Acquired nephrogenic diabetes insipidus and polyuria are found in up to 20% of patients with persistent hypercalcemia and may also contribute to prerenal AKI. Pathophysiology is not completely elucidated, but impairment of the countercurrent mechanism and downregulation of aquaporins 2 and 3 may be involved.²⁹⁻³² It is important to consider that polyuria might represent an adaptive mechanism, for dilution of urinary calcium decreases chances of precipitation in renal tissue.

Chronic hypercalciuria originates Randall plaques, which are calcium-phosphate precipitates on the basement membrane of the thin descending limb of the loop of Henle. These plaques grow towards the tubular lumen or the interstitium, causing nephrolithiasis or nephrocalcinosis, respectively, by serving as anchored sites for calcium-oxalate adhesion.³³⁻³⁶ These effects are responsible for the progression to CKD.¹⁸

The mechanisms of hypercalcemia and their association with kidney injury in ADE users are illustrated in Fig. 1.

Kidney damage due to the use of anabolic steroids

Testosterone and its synthetic hormonal derivatives are collectively called AAS, given their anabolic and androgenic effects. More studies are being performed in order to develop substances with predominant anabolic action.^{8,37,38} Such substances would reduce adverse effects such as testicular atrophy, infertility, erectile dysfunction, gynecomastia and loss of libido.⁸

In the United States, the most frequently used AAS by high performance athletes, are testosterone, stanozolol, nandrolone and boldenone.⁸ Among amateur bodybuilders, boldenone, nandrolone, trenbolone and testosterone are the most common.⁷ A study performed by Iriart et al.³⁹ in Northeast Brazil indicated testosterone and nandrolone as the most often used AAS.

A six-year follow-up study by El-Reshaid et al.⁴⁰ analyzes renal biopsies of 22 AAS and growth hormone (GH) users with high-protein dietary intake who were referred to the local nephrology unit due to altered renal function, hematuria and/or proteinuria. Focal segmental glomerulosclerosis (FSGS) was found in 8 patients, nephroangiosclerosis in 4; chronic interstitial nephritis (CIN) in 3; acute interstitial nephritis (AIN) in 2; nephrocalcinosis with CIN in 2; membranous glomerulopathy in 1; crescentic glomerulopathy in 1; and sclerosing glomerulonephritis in 1. All patients with nephrocalcinosis were hypercalcemic and reported high consumption of milk (in average, 10 l per day) instead of water, in order to increase protein intake. During the follow-up, it was observed that patients diagnosed with FSGS had longer exposure to AAS, later disease onset and worse prognosis. On the other hand, patients with interstitial disease, as CIN or AIN, had shorter exposure to AAS and earlier disease onset, with stabilization or improvement after withholding AAS.⁴⁰

Herlitz et al.⁴¹ studied renal biopsies of 10 AAS users who presented proteinuria and renal failure. Nine patients were diagnosed with FSGS. Direct glomerular toxicity by AAS and glomerular hyperfiltration due to increased body mass (similarly to obesity) were proposed as mechanisms of injury. Doublier et al.⁴² conducted experimental studies with female estrogen receptor knockout mice and also demonstrated the development of glomerulosclerosis. It was concluded that androgen and estrogen receptors in podocytes have opposite

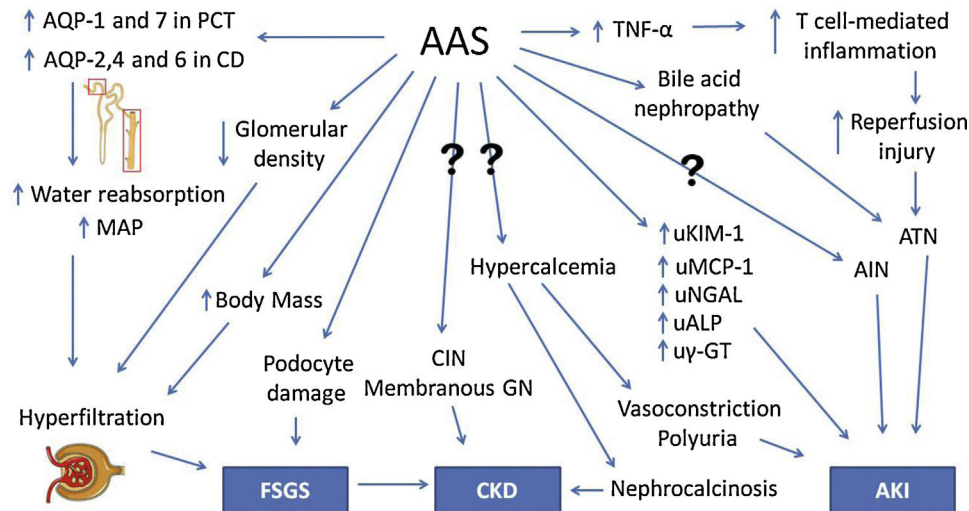


Fig. 2 – Pathophysiology of kidney injury due to AAS use. AAS, anabolic androgenic steroids. Question marks indicate mechanisms that are not understood. AQP, aquaporin. PCT, proximal convoluted tubule. CD, collecting duct. MAP, mean arterial pressure. FSGS, focal segmental glomerulosclerosis. TNF- α , tumor necrosis factor α . ATN, acute tubular necrosis. AIN, acute interstitial nephritis. CIN, chronic interstitial nephritis. GN, glomerulonephropathy. uKIM-1, urinary kidney injury molecule 1. uMCP-1, urinary monocyte chemoattractant protein 1. uNGAL, urinary neutrophil gelatinase-associated lipocalin. uALP, urinary alkaline phosphatase. u γ -GT, urinary γ -glutamyl transpeptidase. CKD, chronic kidney disease. AKI, acute kidney injury.

effects: the former induces damage and apoptosis while the latter has a protective effect.

Satoshi et al.⁴³ have performed an experiment with orchidectomized rats that suggested a testosterone-mediated increase in urinary leucine aminopeptidase (LAP), γ -glutamyl transpeptidase (γ -GT) and alkaline phosphatase (ALP), which are enzymes present on the brush border membrane (BBM). Although also present elsewhere in the human body, they are too large to undergo glomerular filtration, hence their presence in the urine indicates renal damage or their upregulation on the BBM. Urinary glucose, cystatin C and β 2-microglobulin, which are reabsorbed by renal tubules, were also increased by testosterone.

Another experimental study by Patil et al.⁴⁴ with male rats found a protective effect of low-dose testosterone against ischemia-reperfusion injury. However, a higher dose increased TNF- α and intrarenal T cells, failing to elicit a protective effect. Therefore, TNF- α is possibly a key cytokine involved in AAS-associated renal damage. Loh et al.⁴⁵ demonstrated testosterone-mediated increased expression of aquaporins (AQPs)-1 and 7 in the proximal convoluted tubule (PCT) and AQPs-2,4 and 6 in the collecting duct (CD) and consequent elevation of mean arterial pressure (MAP) in rats. This finding suggests that AAS could increase water reabsorption, causing hypertension and chronic kidney disease.

Urological changes may also be involved in AAS renal damage. Shortliffe et al.⁴⁶ observed an increased bladder-to-body mass ratio and a lower collagen-to-smooth muscle ration in the bladder of rats treated with testosterone. Kidney-to-body mass ratio was also increased, although there was a lower glomerular density in the group treated with testosterone.

In order to increase bioavailability and enable oral administration, 17- α -alkylation of AAS molecules has been performed. Stanozolol, one of the most frequently used AAS, is an example of a 17- α -alkylated androgen. However, these steroids are known to be hepatotoxic and cases of severe cholestasis associated with AKI have been reported.^{47,48} Bile acid nephropathy is thought to be the pathophysiologic mechanism of renal impairment in these patients.⁴⁷ Besides hepatic tumors, such as adenoma, which is well associated with AAS, there are also isolated reports of Wilms tumor.⁴⁹ In addition, hypercalcemia and nephrocalcinosis in AAS users who had not received intramuscular oily solutions have also been reported.^{50,51} The underlying pathophysiology in these patients is still elusive.⁵²⁻⁵⁴

An experimental study with rats conducted by Frankenfild et al.⁵⁵ revealed disruption in redox homeostasis in the liver, heart and kidneys of animals treated with AAS. Chronic kidney disease in AAS users is usually asymptomatic for a long time before diagnosis. Moreover, given their increased muscle mass, creatinine levels are frequently elevated in this group of patients, even when renal damage is absent. Therefore, new strategies are needed for accurate and timely diagnosis, and novel biomarkers are currently being studied for that purpose. Daher et al.⁵⁶ conducted a recent study and demonstrated an increase in creatinine and monocyte chemoattractant protein-1 (MCP-1) levels among AAS users, suggesting subclinical renal inflammation. It was our group's first study to analyze the role of novel biomarkers in AAS-related kidney injury. The pathophysiology of renal damage due to AAS use is summarized in Fig. 2.

Conclusions

The inadvisable use of AAS and parenteral vitamins is a public health issue. Parenteral ADE is well associated with vitamin D overload and hypercalcemia, which probably derives from 1- α -hydroxylase-producing granulomas as well as absorption of the injected vitamin D. Hypercalcemia leads to nephrocalcinosis, nephrolithiasis and prerenal AKI. In AAS abuse, glomerular and interstitial damage occur by direct renal toxicity, glomerular hyperfiltration and hypercalcemia. Novel biomarkers for early diagnosis are currently being studied. High levels of MCP-1 were associated with AAS use. Larger studies are needed, since the majority of evidence is based on case and series reports. Finally, raising awareness of the risks and the great health burden of AAS and ADE abuse is probably the best strategy available at the moment for preventing complications.

Key points

- Steroid and vitamin supplements abuse is a public health problem that can cause kidney injury, including acute kidney injury and chronic kidney disease.
- The most frequent and severe complication associated with vitamin supplement abuse is related with extreme doses of vitamin D, which leads to hypercalcemia, calcifications and renal damage.
- Anabolic steroids use has been associated with glomerular abnormalities and proteinuria.
- Novel biomarkers could be important to early detect kidney injury associated with the use of these substances and prevent further injury.

Conflict of interest

The authors declare no conflicts of interest.

Acknowledgements

We are very grateful for the technical support provided for the development of this revision. E.F. Daher, G.B. Silva Junior and A.M.C Martins are recipients of a grant from the Conselho Nacional de Desenvolvimento Científico e Tecnológico (CNPq) and Coordenação de Aperfeiçoamento de Pessoal de Nível Superior (CAPES).

REFERENCES

1. Pope HG, Khalsa JH, Bhasin S. Body image disorders and abuse of anabolic-androgenic steroids among men. *JAMA*. 2017;317:23-4.
2. American Psychiatric Association. Diagnostic and statistical manual of mental disorders. 5th ed. Arlington: American Psychiatric Association; 2013. p. 242-7.
3. Cafri G, Olivardia R, Thompson JK. Symptom characteristics and psychiatric comorbidity among males with muscle dysmorphia. *Compr Psychiatry*. 2008;49:374-9.
4. Dodge T, Hoagland MF. The use of anabolic androgenic steroids and polypharmacy: a review of the literature. *Drug Alcohol Depend*. 2011;114:100-9.
5. Figueiredo VC, Silva PRP, Trindade RS, Rose EH. Doping cosmético: a problemática das aplicações intramusculares de óleos. *Rev Bras Med Esporte*. 2011;17:56-61.
6. Ip EJ, Barnett MJ, Tenerowicz MJ, Perry PJ. The Anabolic 500 survey: characteristics of male users versus nonusers of anabolic-androgenic steroids for strength training. *Pharmacotherapy*. 2011;31:757-66.
7. Pope HG Jr, Kanayama G, Athey A, Ryan E, Hudson JI, Baggish A. The lifetime prevalence of anabolic-androgenic steroid use and dependence in Americans: current best estimates. *Am J Addict*. 2014;23:371-7.
8. Pope HG Jr, Wood RI, Rogol A, Nyberg F, Bowers L, Bhasin S. Adverse health consequences of performance-enhancing drugs: an Endocrine Society scientific statement. *Endocr Rev*. 2014;35:341-75.
9. Abrahim OS, Sousa EC, Santos AM. Prevalence of the use of anabolic-androgenic steroids in Brazil: a systematic review. *Subst Use Misuse*. 2014;49:1156-62.
10. Sjoqvist F, Garle M, Rane A. Use of doping agents, particularly anabolic steroids, in sports and society. *Lancet*. 2008;371:1872-82.
11. Nieschlag E, Vorona E. Doping with anabolic androgenic steroids (AAS): adverse effects on non-reproductive organs and functions. *Rev Endocr Metab Disord*. 2015;16:199-211.
12. Libório AB, Nasseralla JC, Gondim AS, Daher EF. The case: renal failure in a bodybuilder athlete diagnosis: nephrocalcinosis secondary to exogenous vitamin D intoxication. *Kidney Int*. 2014;85:1247-8.
13. Daher EF, Silva Júnior GB, Queiroz AL, Ramos LM, Santos SQ, Barreto DM, et al. Acute kidney injury due to anabolic steroid and vitamin supplement abuse: report of two cases and a literature review. *Int Urol Nephrol*. 2009;4:717-23.
14. Rocha PN, Santos CS, Avila MO, Neves CL, Bahiense-Oliveira M. Hypercalcemia and acute kidney injury caused by abuse of a parenteral veterinary compound containing vitamins A, D, and E. *J Bras Nefrol*. 2011;33:467-71.
15. Almukhtar SE, Abbas AA, Muhealdeen DN, Hughson MD. Acute kidney injury associated with androgenic steroids and nutritional supplements in bodybuilders. *Clin Kidney J*. 2015;8:415-9.
16. Bento C, Velho P, Carvalho M. Lots of steroids and vitamins, tons of complications. Hypercalcemia and nephrocalcinosis as important complications of performance-enhancing drugs. *Nefrologia*. 2015;35:598-600.
17. Ronsoni MF, Santos HC, Colombo BS, Correa CG, Moritz APG, Coral MHC, et al. Hipercalcemia e insuficiência renal aguda após uso de suplemento veterinário. *J Bras Nefrol*. 2017;39:467-9.
18. Daher EF, Martiniano LVM, Lima LLL, Leite Filho NCV, Souza LEO, Fernandes PHD, et al. Acute kidney injury due to excessive and prolonged intra-muscular injection of veterinary supplements containing vitamins A, D and E. A series of 16 cases. *Nefrologia*. 2017;37:61-7.
19. Improving Global Outcomes (KDIGO) Acute Kidney Injury Work Group KDIGO clinical practice guideline for acute kidney injury. *Kidney Int Suppl*. 2012;2:1-138.
20. Tachamo N, Donato A, Timilsina B, Nazir S, Lohani S, Dhital R, et al. Hypercalcemia associated with cosmetic injections: a systematic review. *Eur J Endocrinol*. 2018;178:425-30.
21. Zehnder D, Bland R, Williams MC, McNinch RW, Howie AJ, Stewart PM, et al. Extrarenal expression of 25-hydroxyvitamin

- D (3)-1 alpha-hydroxylase. *J Clin Endocrinol Metab.* 2001;86:888-994.
22. Bhalla KH, Ennis DM, Ennis ED. Hypercalcemia caused by iatrogenic hypervitaminosis A. *J Am Diet Assoc.* 2005;105:119-21.
 23. Sharma OP. Hypercalcemia in granulomatous disorders: a clinical review. *Curr Opin Pulm Med.* 2000;6:442-7.
 24. Frame B, Jackson CE, Reynolds WA, Umphrey JE. Hypercalcemia and skeletal effects in chronic hypervitaminosis A. *Ann Intern Med.* 1974;80:44-8.
 25. Saneshige S, Mano H, Tezuka K, Kakudo S, Mori Y, Honda Y. Retinoic acid directly stimulates osteoclastic bone resorption and gene expression of cathepsin K/OC-2. *Biochem J.* 1995;309:721-4.
 26. Belanger LF, Clark I. Alpharadiographic and histological observations on the skeletal effects of hypervitaminoses A and D in the rat. *Anat Rec.* 1967;158:443-51.
 27. Levi M, Ellis MA, Berl T. Control of renal hemodynamics and glomerular filtration rate in chronic hypercalcemia. Role of prostaglandins, renin-angiotensin system, and calcium. *J Clin Invest.* 1983;71:1624-32.
 28. Sternlicht H, Glezerman IG. Hypercalcemia of malignancy and new treatment options. *Ther Clin Risk Manag.* 2015;11:1779-88.
 29. Wang W, Li C, Kwon TH, Knepper MA, Frøkiaer J, Nielsen S. Aqp3, p-aqp2, and aqp2 expression is reduced in polyuric rats with hypercalcemia: Prevention by camp-pde inhibitors. *Am J Physiol Ren Physiol.* 2002;283:1313-25.
 30. Sands JM, Flores FX, Kato A, Baum MA, Brown EM, Ward DT, et al. Vasopressin-elicited water and urea permeabilities are altered in IMCD in hypercalcemic rats. *Am J Physiol.* 1998;274:978-85.
 31. Hebert SC, Brown EM, Harris HW. Role of the Ca(2+)-sensing receptor in divalent mineral ion homeostasis. *J Exp Biol.* 1997;200:295-302.
 32. Bustamante M, Hasler U, Leroy V, de Seigneux S, Dimitrov M, Mordasini D, et al. Calcium-sensing receptor attenuates AVP-induced aquaporin-2 expression via a calmodulin-dependent mechanism. *J Am Soc Nephrol.* 2008;19:109-16.
 33. Randall A. The origin and growth of renal calculi. *Ann Surg.* 1937;105:1009-27.
 34. Randall A. Papillary pathology as precursor of primary renal calculus. *J Urol.* 1940;44:580-9.
 35. Evan AP, Lingeman JE, Coe FL, Parks JH, Bledsoe SB, Shao Y, et al. Randall's plaque of patients with nephrolithiasis begins in basement membranes of thin loops of Henle. *J Clin Invest.* 2003;111:607-16.
 36. Sayer JA, Carr G, Simmons NL. Nephrocalcinosis: molecular insights into calcium precipitation within the kidney. *Clin Sci.* 2004;106:549-61.
 37. Bhasin S, Jasuja R. Selective androgen receptor modulators (SARMs) as function promoting therapies. *Curr Opin Clin Nutr Metab Care.* 2009;12:232-40.
 38. Narayanan R, Coss CC, Dalton JT. Development of selective androgen receptor modulators (SARMs). *Mol Cell Endocrinol.* 2018;465:134-42.
 39. Iriart JAB, Andrade TM. Body-building, steroid use, and risk perception among young body-builders from a low-income neighbourhood in the city of Salvador, Bahia State, Brazil. *Cad Saude Publica.* 2002;18:1379-87.
 40. El-Reshaid W, El-Reshaid K, Al-Bader S, Ramadan A, Madda JP. Complementary bodybuilding: a potential risk for permanent kidney disease. *Saudi J Kidney Dis Transpl.* 2018;29:326-31.
 41. Herlitz LC, Markowitz GS, Farris AB, Schwimmer JA, Stokes MB, Kunis C, et al. Development of focal segmental glomerulosclerosis after anabolic steroid abuse. *J Am Soc Nephrol.* 2010;21:163-72.
 42. Doublier S, Lupia E, Catanuto P, Periera-Simon S, Xia X, Korach K, et al. Testosterone and 17beta-estradiol have opposite effects on podocyte apoptosis that precedes glomerulosclerosis in female estrogen receptor knockout mice. *Kidney Int.* 2011;79:404-13.
 43. Tsuji S, Sugiura M, Tsutsumi S, Yamada H. Sex differences in the excretion levels of traditional and novel urinary biomarkers of nephrotoxicity in rats. *J Toxicol Sci.* 2017;42:615-27.
 44. Patil CN, Wallace K, LaMarca BD, Moulana M, Lopez-Ruiz A, Soljancic A, et al. Low-dose testosterone protects against renal ischemia-reperfusion injury by increasing renal IL-10-to-TNF- α ratio and attenuating T-cell infiltration. *Am J Physiol Renal Physiol.* 2016;311:F395-403.
 45. Loh SY, Giribabu N, Salleh N. Effects of gonadectomy and testosterone treatment on aquaporin expression in the kidney of normotensive and hypertensive rats. *Exp Biol Med.* 2017;242:1376-86.
 46. Shortliffe LM, Ye Y, Behr B, Wang B. Testosterone changes bladder and kidney structure in juvenile male rats. *J Urol.* 2014;191:1913-9.
 47. Luciano RL, Castano E, Moeckel G, Perazella MA. Bile acid nephropathy in a bodybuilder abusing an anabolic androgenic steroid. *Am J Kidney Dis.* 2014;64:473-6.
 48. Flores A, Nustas R, Nguyen HL, Rahimi RS. Severe cholestasis and bile acid nephropathy from anabolic steroids successfully treated with plasmapheresis. *ACG Case Rep J.* 2016;3:133-5.
 49. Prat J, Gray GF, Stolley PD, Coleman JW. Wilms tumor in an adult associated with androgen abuse. *JAMA.* 1977;237:2322-3.
 50. Samaha AA, Nasser-Eddine W, Shatila E, Haddad JJ, Wazne J, Eid AH. Multi-organ damage induced by anabolic steroid supplements: a case report and literature review. *J Med Case Rep.* 2008;2:340.
 51. Luchi WM, Ricarte RN, Roitman LF, Santos Oda R. Nephrocalcinosis associated with the use of anabolic steroid. *J Bras Nefrol.* 2015;37:135-40.
 52. Unai S, Miessau J, Karbowski P, Baram M, Cavarocchi NC, Hirose H. Caution for anabolic androgenic steroid use: a case report of multiple organ dysfunction syndrome. *Respir Care.* 2013;58:159-63.
 53. Hughes M, Ahmed S. Anabolic androgenic steroid induced necrotising myopathy. *Rheumatol Int.* 2011;31:915-7.
 54. Farkash U, Shabshin N, Pritsch Perry M. Rhabdomyolysis of the deltoid muscle in a bodybuilder using anabolic-androgenic steroids: a case report. *J Athl Train.* 2009;44:98-100.
 55. Frankenfeld SP, Oliveira LP, Ortenzi VH, Rego-Monteiro IC, Chaves EA, Ferreira AC, et al. The anabolic androgenic steroid nandrolone decanoate disrupts redox homeostasis in liver, heart and kidney of male Wistar rats. *PLOS ONE.* 2014;9:e102699.
 56. Daher EF, Fernandes PHPD, Meneses GC, Bezerra GF, Ferreira LSL, Viana GA, et al. Novel kidney injury biomarkers among anabolic androgenic steroids users – evidence of subclinical kidney disease. *Asian J Sports Med.* 2018;9:e65540.