

warfarin, calcium-containing antiphosphate medication and Vitamin D.<sup>3</sup> The risk factors for our case are obesity, female gender, diabetes mellitus and calcium-containing antiphosphate medication. Halasz et al. mentioned recently that the diagnosis of calciphylaxis may be done by radiologic techniques such as direct radiography, mammography or CT prior to receiving histopathological results.<sup>9</sup> Radiography of the extremities in our case showed linear vascular calcification.

Coexistence of these two rare entities- NSF and calciphylaxis- was published in three cases in the literature.<sup>4,5</sup> Edsall et al. documented a report of two cases who were clinically typical of NSF with evident vascular calcification on skin biopsy like calciphylaxis, but had no clinical features of calciphylaxis. They mentioned NSF may be a predisposing factor for calciphylaxis in early stages, or calcification may play a role in the pathophysiology of NSF. They also thought fibrosis and calcification in kidney failure may be the result of increased activity of transforming growth factor- $\beta$ /Smad signaling cascades.<sup>4</sup> Lewis et al. reported a case of NSF and calciphylaxis with pseudoxanthoma elasticum-like changes in the same localization.<sup>5</sup> In our case the infraumbilical-localized lesion of our patient revealed the diagnosis of NSF with vascular calcification-like calciphylaxis. By describing this case we want to emphasize that, although microscopic calcification has been reported in the skin biopsies of NSF, coexistence of the calciphylaxis and nephrogenic systemic fibrosis with different localizations may be seen. To the best of our knowledge this is the first case of coexistence of the calciphylaxis and nephrogenic systemic fibrosis with different localizations in a hemodialysis patient. This situation may be explained with consociate etiological origin.

### Conflict of interest

None.

### REFERENCES

1. Cowper SE, Robin HS, Steinberg SM, Su LD, Gupta S, LeBoit PE. Scleromyxoedema-like cutaneous diseases in renal-dialysis patients. *Lancet*. 2000;356:1000-1.
2. Caccetta T, Chan JJ. Nephrogenic systemic fibrosis associated with liver transplantation, renal failure and gadolinium. *Aust J Dermatol*. 2008;49:48-51.
3. Brewster UC. Dermatological disease in patients with CKD. *Am J Kidney Dis*. 2008;51:331-44.
4. Edsall LC, English JC, Teague MW, Patterson JW. Calciphylaxis and metastatic calcification associated with nephrogenic fibrosing dermopathy. *J Cutan Pathol*. 2004;31:247.
5. Lewis KG, Lester BW, Pan TD, Robinson-Boston L. Nephrogenic fibrosing dermopathy and calciphylaxis with pseudoxanthoma elasticum-like changes. *J Cutan Pathol*. 2006;33:695.
6. Anavekar NS, Chong AH, Norris R, Dowling J, Goodman D. Nephrogenic systemic fibrosis in a gadolinium-naive renal transplant recipient. *Australas J Dermatol*. 2008;49:44-7.
7. Ross C, De Rosa N, Marshman G, Astill D. Nephrogenic systemic fibrosis in a gadolinium-naive patient: successful treatment with oral sirolimus. *Australas J Dermatol*. 2015;56:e59-62.
8. Deng AC, Bilu Martin D, Sina B, Gaspari A. Localized nephrogenic fibrosing dermopathy: aberrant dermal repairing? *J Am Acad Dermatol*. 2008;58:336-9.
9. Halasz CL, Munger DP, Frimmer H, Dicorato M, Wainwright S. Calciphylaxis: comparison of radiologic imaging and histopathology. *J Am Acad Dermatol*. 2017;77, 241-246.e3.

Muge Gore Karaali<sup>a,\*</sup>, Vefa Aslı Turgut Erdemir<sup>b</sup>, Cem Leblebici<sup>c</sup>, Ozan Erdem<sup>a</sup>, Asude Kara Polat<sup>a</sup>, Mehmet Salih Gurel<sup>b</sup>

<sup>a</sup> Department of Dermatology, Istanbul Training and Research Hospital, Istanbul, Turkey

<sup>b</sup> Department of Dermatology, Medeniyet University, Faculty of Medicine, Istanbul, Turkey

<sup>c</sup> Department of Pathology, Istanbul Training and Research Hospital, Istanbul, Turkey

\* Corresponding author.

E-mail address: [mugegore@hotmail.com](mailto:mugegore@hotmail.com) (M. Gore Karaali).

0211-6995/© 2019 Sociedad Española de Nefrología. Published by Elsevier España, S.L.U. This is an open access article under the CC BY-NC-ND license (<http://creativecommons.org/licenses/by-nc-nd/4.0/>).

<https://doi.org/10.1016/j.nefro.2019.03.011>

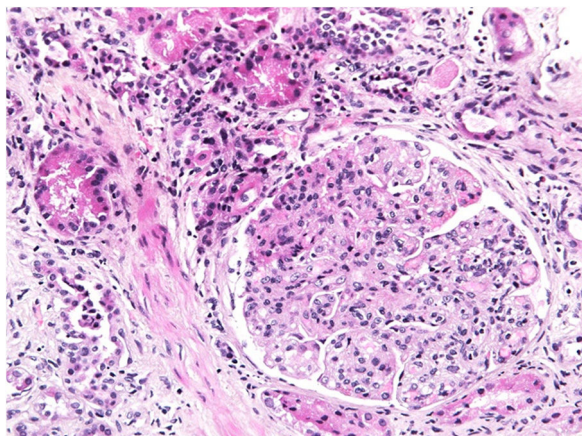
## Collagen type III nephropathy as a systemic disease? – A case report

### Glomerulopatía por colágeno tipo III como enfermedad sistémica: caso clínico

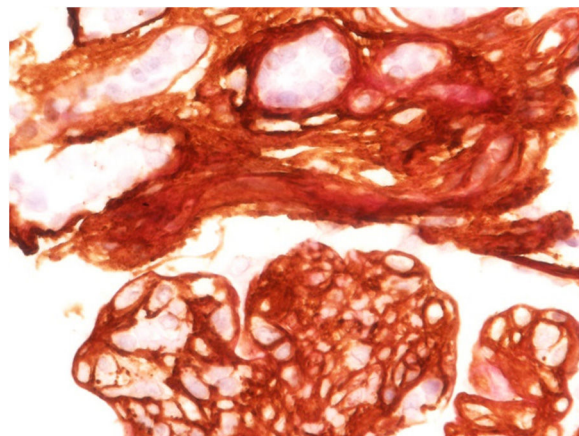
Dear Editor:

We present a case of a 57-year old female who complained of progressive weight loss, general weakness, dysphagia and

mild bilateral leg swelling. She had a history of asthma, arterial hypertension, hypothyroidism due to Hashimoto thyroiditis and axonal sensorimotor polyneuropathy of unknown cause. She had no family history of renal disease. General and systemic



**Fig. 1 – Diffuse global proliferative glomerulonephritis with lobulation of glomeruli (HE, 20×).**



**Fig. 2 – Brown staining of collagen III in the interstitial space, in expanded mesangium and in subendothelial areas (immunoperoxidase reaction with anti-collagen III antibody, 60×).**

examination was unremarkable except minimal peripheral leg edema and mildly atrophic lower limb musculature. She had no nail or patella dysplasia.

Blood test results: creatinine 110  $\mu\text{mol/L}$ ; CKD-EPI glomerular filtration rate 48 ml/min/1.73 m<sup>2</sup>, cystatin C 2.8 mg/dL, mildly elevated gamma glutamyl transferase and alkaline phosphatase, hypoalbuminemia 32 g/L, positive ANA H+ (1:160).

Urine test results: microhematuria and proteinuria 4 g per day.

Diagnostic procedures revealed mild to moderate pulmonary hypertension, mild pericardial effusion, hepatosplenomegaly, bilateral minimal pleural effusion and ascites (exudate with negative cytology results).

Renal biopsy revealed a diffuse endoproliferative (mesangioproliferative pattern) exudative sclerosing glomerulonephritis with collagen III deposition within mesangium and capillary walls, accompanied with diffuse chronic fibrosing mononuclear tubulo-interstitial nephritis. Immunocomplex glomerulonephritides were excluded (Figs. 1 and 2).

Measurement of N-terminal peptide of type III procollagen (PIIP) in serum (19.2 ng/mL) and urine (53.6 ng/mL) was performed (RIA-gnost<sup>®</sup> PIIP kit, Cisbio Bioassays).

Our patient was discharged with furosemide and angiotensin-converting-enzyme (ACE) inhibitor. On follow-up her renal function was stable. In a few months she died at home. Unfortunately the autopsy was not performed and the cause of death remained unknown.

Collagen type III nephropathy (Col3NP) is a rare glomerular disease with characteristic accumulation of abnormal collagen type III in glomerular mesangium and subendothelial space and increase in serum PIIP levels.<sup>1</sup> The etiopathogenesis remains unclear, but ethnic and/or genetic factors may play a role.<sup>2</sup> Some authors suggested autosomal recessive inheritance pattern, whereas in our case the occurrence of disease was sporadic.<sup>3</sup>

The most common clinical presentation is proteinuria, which is in the nephrotic range in more than 50% of the patients, with or without associated nephrotic syndrome. Hematuria is microscopic. Arterial hypertension is present in

approximately 60% of the patients. Renal function is usually normal or slightly reduced at presentation, but in 50% there is progression to end-stage renal disease (ESRD).<sup>3</sup> Our patient presented with nephrotic range proteinuria and microscopic hematuria but without arterial hypertension. She had chronic kidney disease (CKD) stage 3. Our histology findings from renal biopsy were consistent with data from literature presenting patients with Col3NP.<sup>2,3</sup>

Type III collagen is a structural protein of extracellular matrix and is present in tissues showing elastic properties. In kidney it is normally present only in the interstitium and blood vessels, but not in the glomerulus.<sup>4</sup> Although the pathogenesis of this disease is still unknown, two explanations have been proposed. One is the mesangial production of abnormal collagen, another is mesangial accumulation of type III collagen derived from other organs.<sup>5</sup>

The disease is mainly limited to kidneys, but there are a few isolated reports of extra-renal involvement with Col3NP leading to a hypothesis that renal lesion may be a part of a systemic disease with abnormal metabolism of type III collagen.<sup>5</sup> Abnormal collagen III fibers have been found in liver, spleen and kidneys and in some other organs (myocardium, pancreas, thyroid gland, alveoli).<sup>5</sup> According to clinical examination and all pathological findings we believed that our patient had some kind of systemic disease. She had multiple organ damage which we could not explained otherwise. She developed hepatosplenomegaly with ascites. Without biopsy of the liver etiology of liver disease in our patient remained unknown, however we excluded other common causes (viral hepatitis, alcohol consumption, cirrhosis, hemochromatosis, cancer, intoxication, etc.). Since there is data from literature that collagen III deposition was found in spleen and liver in some patients with confirmed Col3NP, we assumed that was the cause in our patient as well. Furthermore, unexplained polyneuropathy of our patient may as well be caused by abnormal collagen III deposition in nervous system, since common neurological diseases were excluded. Additionally, there was also unexplained pulmonary hypertension.

Unfortunately, Col3NP is a progressive disease and no specific therapy is available. Supportive measures include control of arterial hypertension, diuretics to relieve edema and renal replacement therapy if needed.<sup>4</sup> Steroids, cyclosporine, cyclophosphamide and low-density lipoprotein apheresis had been tried with no benefit.<sup>6</sup> The progression of the disease is assumed to depend on the extent of deposition and the amount of tubulointerstitial fibrosis and atrophy.<sup>7</sup> In an isolated renal pathology the worst end point is progression to ESRD, whereas in a systemic involvement there is progression to multiorgan failure and death. We can speculate, that in a systemic type of disease with multiple organs affected, the progression is even faster. We assumed that was the case in our patient – she died a few months after the diagnosis.

#### REFERENCES

1. Patro KC, Jha R, Sahay M, Swarnalatha G. Collagenofibrotic glomerulopathy – case report with review of literature. *Indian J Nephrol.* 2011;21:52–5.
2. Duggal R, Nada R, Rayat CS, Rane SU, Sakhuja V, Joshi K. Collagenofibrotic glomerulopathy – a review. *Clin Kidney J.* 2012;5:7–12.
3. Cohen AH. Collagen type III glomerulopathies. *Adv Chronic Kidney Dis.* 2012;19:6–101.
4. Alchi B, Nishi S, Narita I, Gejyo F. Collagenofibrotic glomerulopathy: clinicopathologic overview of a rare glomerular disease. *Am J Kidney Dis.* 2007;49:499–506.

5. Yasuda T, Imai H, Nakamoto Y, Ohtani H, Komatsuda A, Wakui H, et al. Collagenofibrotic glomerulopathy: a systemic disease. *Am J Kidney Dis.* 1999;33:123–7.
6. Goto S, Nakai K, Ito J, Fujii H, Tasaki K, Suzuki T, et al. Marked elevation of serum hyaluronan levels in collagenofibrotic glomerulopathy. *Intern Med.* 2014;53:4–1801.
7. Anitha A, Vankalakunti M, Siddini V, Babu K, Bonu R, Ballal S, et al. collagen disorders: a case report and review of literature. *Indian J Pathol Microbiol.* 2016;59:75–7.

Eva Jakopin<sup>a,\*</sup>, Sebastjan Bevc<sup>a,c</sup>, Robert Ekart<sup>b,c</sup>, Radovan Hojs<sup>a,c</sup>

<sup>a</sup> University Medical Centre Maribor, Division of Internal Medicine, Department of Nephrology, Ljubljanska 5, Maribor, Slovenia

<sup>b</sup> University Medical Centre Maribor, Division of Internal Medicine, Department of Dialysis, Ljubljanska 5, Maribor, Slovenia

<sup>c</sup> University of Maribor, Faculty of Medicine, Taborska 5, Maribor, Slovenia

\* Corresponding author.

E-mail address: [eva.jakopin@ukc-mb.si](mailto:eva.jakopin@ukc-mb.si) (E. Jakopin).

0211-6995/© 2019 Sociedad Española de Nefrología. Published by Elsevier España, S.L.U. This is an open access article under the CC BY-NC-ND license (<http://creativecommons.org/licenses/by-nc-nd/4.0/>).  
<https://doi.org/10.1016/j.nefro.2019.04.008>

## Microangiopatía trombótica como recidiva de síndrome antifosfolípido en trasplante renal

### Primary antiphospholipid syndrome presented as thrombotic microangiopathy in renal transplantation

Sr. Director:

La microangiopatía trombótica (MAT) puede ser la forma de inicio de múltiples enfermedades (síndrome hemolítico urémico atípico, síndrome antifosfolípidos [SAF]), ampliándose su diagnóstico diferencial en pacientes portadores de un trasplante renal (rechazo agudo humoral [RAH], toxicidad por inhibidores de la calcineurina). Suele asociar una mala evolución de la función del injerto renal, siendo importante iniciar el tratamiento específico precozmente<sup>1</sup>. En pacientes que presentan MAT asociado a SAF el tratamiento es la anticoagulación, aunque en casos sin respuesta se ha usado ecilizumab con buenos resultados<sup>2</sup>.

Presentamos el caso de una mujer de 60 años con antecedentes personales de hipertensión arterial, cardiopatía isquémica, fibrilación auricular paroxística, portadora de prótesis mecánica mitral y aórtica, 2 abortos y una enfer-

medad renal crónica terminal de etiología no filiada. Como consecuencia de haber recibido múltiples transfusiones y de embarazos, la paciente era hiperinmunitizada. Recibió su primer trasplante renal de donante fallecido, realizándose la inmunosupresión con esteroides, tacrolimus, micofenolato e inducción con 7 dosis de timoglobulina. Por ser portadora de válvulas protésicas se inició anticoagulación con heparina sódica en las primeras 48 h postrasplante. La paciente experimentó desde el 2.º día postrasplante (DPT) un progresivo aumento del ritmo de diuresis, pero sin descenso de la creatinina sérica (Cr<sub>s</sub>). Sin embargo, desde el 7.º DPT presentó una disminución de la diuresis, decidiéndose realizar una biopsia renal en el 12.º DPT. La biopsia mostró 14 glomérulos, 6 de los cuales presentaban trombos capilares, lesiones exudativas y tumefacción endotelial; las arterias radiales presentaban trombos y necrosis fibrinoide; la tinción de C4d fue positiva en los capilares peritubulares (fig. 1). Además, la paciente comenzó a presentar trombocitopenia (86.000/μl),