

# Blood transfusion during haemodialysis improves systemic tissue oxygenation: A case report

## La transfusión de sangre durante la hemodiálisis mejora la oxigenación sistémica del tejido: un reporte de un caso

Dear Editor,

Tissue oxygenation is maintained through various mechanisms, including blood pressure, circulating blood volume, and hemoglobin (Hb) concentration. In particular, Hb itself is considered an important factor because of its oxygen transportation function to systemic organs. Therefore, it is evident that oxygen supply would decrease in a severe anemic state.<sup>1</sup> Recent reports have demonstrated the measurement of regional oxygen saturation (rSO<sub>2</sub>), a real-time marker of tissue oxygenation using near-infrared spectroscopy (NIRS).<sup>2,3</sup> Measurement of rSO<sub>2</sub> by using NIRS is a straightforward non-invasive procedure, which can be performed continuously. Nevertheless, only a few studies have investigated the association between systemic tissue oxygenation and the increase in Hb levels after blood transfusion in hemodialysis (HD) patients. In the current case study, we were able to monitor changes in the rSO<sub>2</sub> of brain, liver, and lower-limb muscles during HD with and without blood transfusion.

A 79-year-old woman undergoing HD was admitted to our hospital with acute obstructive suppurative cholangitis. Upon admission, we administered intravenous antibiotics and performed endoscopic biliary drainage, which resulted in a gradual improvement of her symptoms. Her anemia had been previously managed with an erythropoietin-beta (3000 IU/session, 3 times/week); however, her Hb levels decreased to 6.8 g/dL. Therefore, blood transfusion during HD was performed. She provided written informed consent to participate in monitoring of her systemic rSO<sub>2</sub> during HD with or without blood transfusion. The rSO<sub>2</sub> levels were monitored at the forehead, right hypochondriac region above the liver, and lower leg above the gastrocnemii muscles by using the INVOS 5100c (Covidien Japan). She received a transfusion of 560 mL of concentrated red blood cells during HD and her Hb levels increased from 6.8 to 10.0 g/dL after HD (Table 1). Furthermore, we compared the time course of rSO<sub>2</sub> ratio in each organ, with and without blood transfusion. The rSO<sub>2</sub> ratio was defined as the ratio of rSO<sub>2</sub> values at t (min) during HD and initial rSO<sub>2</sub> value before HD. As shown in Fig. 1, the changes in rSO<sub>2</sub> ratio during HD without blood transfusion were modest in each organ, whereas the rSO<sub>2</sub> ratio at each organ increased with blood transfusion, particularly in cerebral and hepatic regions.

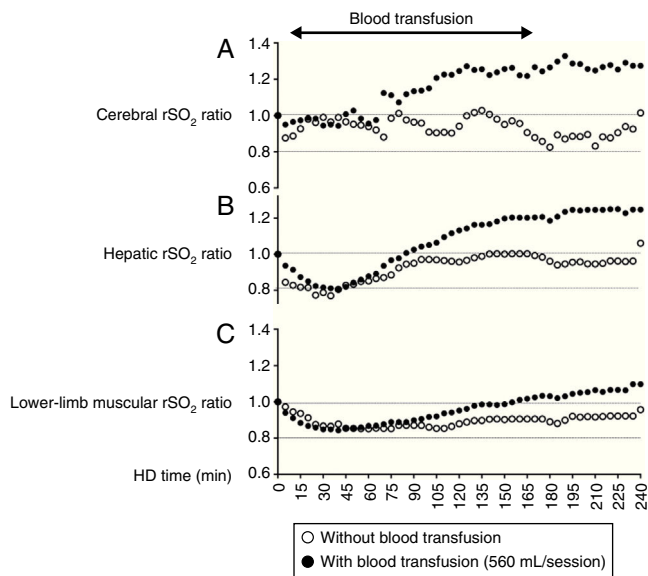
In the world including United States, Europe, and Japan in around 1990, the use of erythropoiesis stimulating agents (ESA) in clinical settings was approved, which dramatically improved the Hb levels in patients with HD. However, even in the present day, blood transfusion during HD is still necessary for improving Hb levels in HD patients with severe anemia. Indeed, in comparison of blood transfusion frequency between ESA responsive and hyporesponsive HD patients, hyporesponsive patients had approximately 5 to 7-fold higher burden of blood transfusion than those with responsiveness.<sup>4</sup> In addition, changes in systemic oxygenation induced by blood transfusion during HD have not been investigated extensively.

The brain has an auto-regulatory mechanism to maintain cerebral oxygenation. In HD patients, normalization of

**Table 1 – Vital signs and laboratory findings under HD with or without blood transfusion.**

	HD without blood transfusion	HD with blood transfusion
<i>Body weight, kg</i>		
Before	59.0	58.9
After	57.8	57.9
<i>BP, mmHg</i>		
Before	147/71	118/93
After	149/74	173/75
<i>Pulse, beats/min</i>		
Before	78	85
After	77	75
<i>Hb, g/dL</i>		
Before	7.1	6.8
After	7.2	10.0
<i>BUN, mg/dL</i>		
Before	38	26
After	7	5
<i>Cr, mg/dL</i>		
Before	4.3	3.7
After	1.0	0.9
<i>Albumin, g/dL</i>		
Before	2.9	2.8
After	3.0	3.0

BP, blood pressure; BUN, blood urea nitrogen; Cr, creatinine; Hb, hemoglobin; HD, hemodialysis.



**Fig. 1** – Changes in regional oxygen saturation ( $rSO_2$ ) of the forehead (A), liver (B), and lower leg (C) as per the oxygenation values of cerebral, hepatic, and muscle tissue, respectively, under hemodialysis (HD) with or without blood transfusion.  $rSO_2$  ratio is defined as the ratio of  $rSO_2$  value at  $t$  (min) during HD and the initial  $rSO_2$  value before HD ( $rSO_2$  at  $t$  (min) during HD/initial  $rSO_2$  before HD).

hematocrit by ESA did not increase cerebral oxygenation.<sup>5</sup> Moreover, cerebral oxygenation in these patients was well-maintained when compared to pre-dialysis patients,<sup>6</sup> and cerebral  $rSO_2$  values did not change by ultrafiltration under well-managed Hb levels.<sup>7</sup> In the present case,  $rSO_2$  values did not change in any organ during HD without blood transfusion, which is similar to a previous report.<sup>7</sup> On the other hand, each  $rSO_2$  values improved with an increase in Hb levels after blood transfusion. Particularly in the brain, oxygen supply decreases in patients with severe anemia<sup>1</sup>; furthermore, acute anemia by phlebotomy induces the deterioration of intracellular oxygen reactions in mice.<sup>8</sup> Thus, presence of severe anemia may lead to a decrease in cerebral oxygenation despite the auto-regulatory mechanism of the brain. Therefore, the improvement of cerebral oxygenation after blood transfusion could be explained by the increase of oxygen-carrying capacity, which is associated with the increase in Hb levels.

Regarding the changes in  $rSO_2$  of each organ after blood transfusion, the improvement of lower-limb muscular  $rSO_2$  was relatively lower than that of cerebral and hepatic  $rSO_2$  even in this case without peripheral artery disease. In HD patients, the prevalence of subclinical peripheral artery disease reached around 20–25%,<sup>9</sup> and its presence may directly influence the lower-limb muscular  $rSO_2$  via a decrease in oxygen supply induced by the dysfunction of macro- and micro-circulation. Furthermore, the skeletal muscle index has been reported to be lower in HD patients than in healthy subjects.<sup>10</sup> Therefore, the changes in lower-limb muscular  $rSO_2$  value during HD might be influenced by the circulatory impairment and skeletal muscle weakness. However, the

mechanism responsible for the differences in  $rSO_2$  improvement between different organs, induced by blood transfusion during HD, remains unclear and requires further investigation.

Our study suggests that blood transfusion during HD could be an effective method to improve tissue oxygenation, particularly cerebral and hepatic oxygenation in HD patients with severe anemia.

## Financing

None.

## Conflict of interest statement

The authors have declared that no conflict of interest exists.

## BIBLIOGRAFÍA

1. Kuwabara Y, Sasaki M, Hirakata H, Koga H, Nakagawa M, Chen T, et al. Cerebral blood flow and vasodilatory capacity in anemia secondary to chronic renal failure. *Kidney Int.* 2002;61:564–9.
2. Ito K, Ookawara S, Ueda Y, Goto S, Miyazawa H, Yamada H, et al. Factors affecting cerebral oxygenation in hemodialysis patients: cerebral oxygenation associates with pH, hemodialysis duration, serum albumin concentration, and diabetes mellitus. *PLOS ONE.* 2015;10:e0117474.
3. Nishiyama K, Ito N, Orita T, Hayashida K, Arimoto H, Beppu S, et al. Regional cerebral oxygen saturation monitoring for predicting interventional outcomes in patients following out-of-hospital cardiac arrest of presumed cardiac cause: a prospective, observational, multicentre study. *Resuscitation.* 2015;96:135–41.
4. Sibbel SP, Koro CE, Brunelli SM, Cobitz AR. Characterization of chronic and acute ESA hyporesponse: a retrospective cohort study of hemodialysis patients. *BMC Nephrol.* 2015;16:144, <http://dx.doi.org/10.1186/s12882-015-0138-x>.
5. Metry G, Wikstrom B, Valind S, Sandhagen B, Linde T, Beshara S, et al. Effect of normalization of hematocrit on brain circulation and metabolism in hemodialysis patients. *J Am Soc Nephrol.* 1999;10:854–63.
6. Kanai H, Hirakata H, Nakane H, Fujii K, Hirakata E, Ibayashi S, et al. Depressed cerebral oxygen metabolism in patients with chronic renal failure: a positron emission tomography study. *Am J Kidney Dis.* 2001;38:129–33.
7. Hoshino T, Ookawara S, Goto S, Miyazawa H, Ito K, Ueda Y, et al. Evaluation of cerebral oxygenation in patients undergoing long-term hemodialysis. *Nephron Clin Prac.* 2014;126:57–61.
8. Hirakata Y, Yoshihara T, Kamiya M, Mimura I, Fujikura D, Masuda T, et al. Quantitating intracellular oxygen tension in vivo by phosphorescence lifetime measurement. *Sci Rep.* 2015;5:17838, <http://dx.doi.org/10.1038/srep17838>.
9. Liu JH, Chen JY, Lin SY, Lin HH, Ting IW, Liang CC, et al. Comparing survival between peritoneal dialysis and hemodialysis patients with subclinical peripheral artery disease: a 6-year follow up. *Int J Med Sci.* 2013;10:434–40.
10. Morishita Y, Kubo K, Miki A, Ishibashi K, Kusano E, Nagata D. Positive association of vigorous and moderate physical activity volumes with skeletal muscle mass but not bone density or metabolism markers in hemodialysis patients. *Int Urol Nephrol.* 2014;46:633–9.

Kiyonori Ito<sup>a</sup>, Susumu Ookawara<sup>a,\*</sup>, Yuichiro Ueda<sup>a</sup>, Takayuki Uchida<sup>b</sup>, Masaya Kofuji<sup>b</sup>, Hideyuki Hayasaka<sup>b</sup>, Taro Hoshino<sup>a</sup>, Kaoru Tabei<sup>c</sup>, Yoshiyuki Morishita<sup>a</sup>

<sup>a</sup> Division of Nephrology, First Department of Integrated Medicine, Saitama Medical Center, Jichi Medical University, Saitama, Japan

<sup>b</sup> Department of Clinical Engineering, Saitama Medical Center, Jichi Medical University, Saitama, Japan

<sup>c</sup> Minami-Uonuma City Hospital, Niigata, Japan

\* Corresponding author.

E-mail address: [su-ooka@hb.tp1.jp](mailto:su-ooka@hb.tp1.jp) (S. Ookawara).

0211-6995/© 2016 Sociedad Española de Nefrología. Published by Elsevier España, S.L.U. This is an open access article under the CC BY-NC-ND license (<http://creativecommons.org/licenses/by-nc-nd/4.0/>).

<http://dx.doi.org/10.1016/j.nefro.2016.10.025>

## Afectación glomerular en paciente con enfermedad falciforme

### Glomerular involvement in patient with sickle cell disease

Sr. Director:

La nefropatía falciforme (NF) es una de las complicaciones que la enfermedad falciforme (EF) puede provocar por la propensión de la hemoglobina S desoxigenada a la polimerización en la médula interna renal, dadas sus condiciones fisiológicas especiales (hiperosmolaridad, hipoxia y acidosis)<sup>1,2</sup>, que contribuye a los fenómenos vasooclusivos típicos de la enfermedad<sup>3</sup>.

La insuficiencia renal crónica y la proteinuria son los factores de riesgo asociados a un incremento de mortalidad en estos pacientes<sup>4</sup>, y la albuminuria, el marcador inicial de glomerulopatía asociada a la EF, cuya expresión más frecuente es en forma de glomerulosclerosis focal y segmentaria (GME FyS)<sup>5,6</sup>. La biopsia renal está indicada en los casos en los que se sospecha glomerulopatía.

Presentamos el caso de un varón de 30 años y raza blanca, con antecedentes de drepanocitosis homocigota que trata con hidroxiurea y deferasirox, desarrolla 1-2 crisis anuales, sin repercusión renal hasta ese momento. Fumador de 3 cigarrillos/día.

Es derivado a consulta por proteinuria de 2,75 g en orina de 24 h (microalbuminuria: 1,5 g/24 h). El sistemático de orina muestra densidad: 1006, ph: 5,5, proteinuria 100 mg/dl y sedimento normal; la función renal es *a priori* normal (Cr: 0,7 mg/dl y MDRD > 60 ml/min); presenta Hb: 10,8 g/dl; Hto: 30% (IST: 80%; ácido fólico: 8,2 ng/ml; VitB: 570 pg/ml) y PCR: 6,6 mg/l. El estudio ampliado con autoinmunidad y virus de la hepatitis C y B, así como VIH resulta negativo. En la ecografía abdominal, los riñones no tienen alteraciones morfológicas y el bazo es pequeño con aumento difuso de ecogenicidad sugiriendo fibrosis tras infartos esplénicos repetidos.

Comprobada por segunda vez el nivel de proteinuria, se decide biopsia renal objetivándose hipertrofia glomerular sin esclerosis, con expansión de los capilares glomerulares y presencia de hematíes falciformes en su interior (fig. 1). Los túbulos presentan células cargadas de hemosiderina con la

tinción de Perls y ocasionales áreas de atrofia asociadas a fibrosis con el tricrómico (fig. 2 A y B). Los vasos intersticiales no revelan alteraciones y la inmunofluorescencia directa ausencia de depósitos.

El paciente es diagnosticado de glomerulopatía específica de la EF. Inició tratamiento con valsartán 80 mg/día consiguiendo un descenso de proteinuria a 1,6 g/24 h (microalbuminuria: 1,1 g/24 h) después de un año y presión arterial media 111/63 mmHg por AMPA, no pudiéndose incrementar dosis de ARA-II ni hacer doble bloqueo del sistema renina-angiotensina por hipotensión sintomática. En la actualidad, la función renal se mantiene con Cr: 0,64 mg/dl (MDRD > 60 ml/min; CKD-EPI: 130 ml/min), fósforo sérico 5 mg/dl (reabsorción tubular de fosfatos: 0,9; reabsorción tubular de urato: 0,9) y sedimento urinario persiste normal.

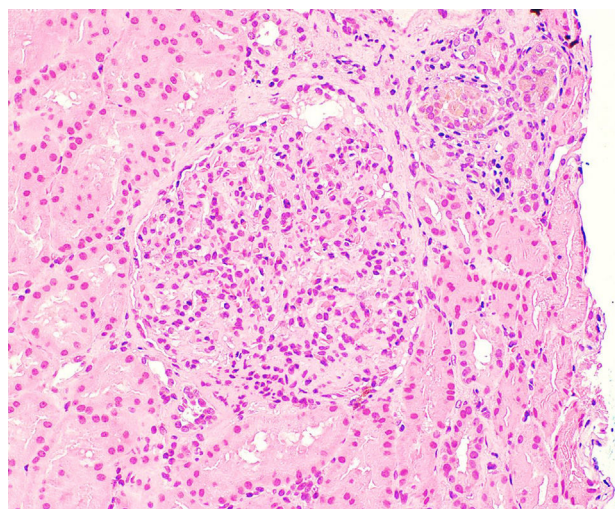


Figura 1 – Hematoxilina eosina. Hipertrofia glomerular.