

- syndrome in secondary renal amyloidosis. *Nefrologia*. 2002;22:482-5.
5. Dember LM, Hawkins PN, Hazenberg BPC, Gorevic PD, Merlini G, Butrimiene I, et al. Eprodisate for the treatment of renal disease in AA amyloidosis. *N Engl J Med*. 2007;356:2349-60.
  6. Olivero JJ, Frommer JP, Gonzalez JM. Medical nephrectomy: the last resort for intractable complications of the nephrotic syndrome. *Am J Kidney Dis*. 1993;21:260-3.
  7. Keller FS, Coyle M, Rosch J, Dotter CT. Percutaneous renal ablation in patients with end-stage renal disease: alternative to surgical nephrectomy. *Radiology*. 1986;159:447-51.
  8. Keddis MT, Stegall MD, Textor SC. Renal ablation using bilateral ureteral ligation for nephrotic syndrome due to renal amyloidosis. *Clin Kidney J*. 2012;5:153-4.
  9. Hopfer H, Wiech T, Mihatsch MJ. Renal amyloidosis revisited: amyloid distribution, dynamics and biochemical type. *Nephrol Dial Transplant*. 2011;26:2877-84.
  10. Esteve V, Almirall J, Ponz E, García N, Ribera L, Larrosa M, et al. Afectación renal en la amiloidosis. Características clínicas, evolución y supervivencia. *Nefrologia*. 2006;26:212-7.

Sandra Silva<sup>a,\*</sup>, Ricardo Pereira<sup>b</sup>, Ivo Cunha<sup>b</sup>, Carlos Ferreira<sup>c</sup>, Ana Branco<sup>a</sup>, Eduardo Eiras<sup>b</sup>, Mrinalini Honavar<sup>d</sup>, Joana Simões<sup>b</sup>, Teresa Santos<sup>a</sup>, Teresa Chuva<sup>a</sup>, José Costa<sup>a</sup>

<sup>a</sup> Nephrology, Hospital Pedro Hispano, Porto, Portugal

<sup>b</sup> Internal Medicine, Hospital Pedro Hispano, Porto, Portugal

<sup>c</sup> Urology, Hospital Pedro Hispano, Porto, Portugal

<sup>d</sup> Pathology, Hospital Pedro Hispano, Porto, Portugal

\*Corresponding author.

E-mail address: [oliveirasilva.sandra@gmail.com](mailto:oliveirasilva.sandra@gmail.com) (S. Silva).

0211-6995/© 2016 Sociedad Española de Nefrología. Published by Elsevier España, S.L.U. This is an open access article under the CC BY-NC-ND license (<http://creativecommons.org/licenses/by-nc-nd/4.0/>).

<http://dx.doi.org/10.1016/j.nefro.2016.03.016>

## BK virus nephropathy in a renal transplant patient: Potential role of electron microscopy in diagnosis

### Nefropatía por virus BK en un paciente con trasplante renal: Papel potencial de la microscopía electrónica en el diagnóstico

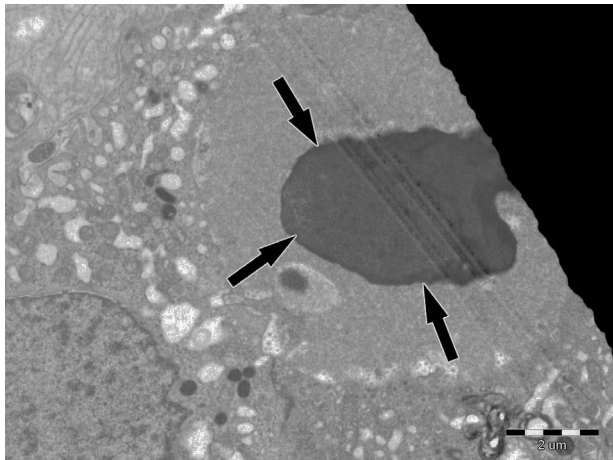
Dear Editor,

BK polyomavirus (BKV) causes latent, asymptomatic infection in immunocompetent individuals. In the setting of immunosuppression BKV can reactivate and lead to BK virus nephropathy (BKVN) in renal transplant recipients.<sup>1</sup> BKVN is one of the main causes of allograft failure in renal transplant patients. Acute rejection and different viral infections should be considered in differential diagnosis of renal allograft dysfunction. Electron microscopy (EM) could help to distinguish BKV from other viral factors in allograft tissue.<sup>2</sup> Herein, we described inclusions due to BKV seen by EM in a renal transplant biopsy and we discussed potential role of EM in diagnosis of BKVN.

A 49 years old woman had renal transplantation from non-relative donor 2 years ago. Although she was asymptomatic, her serum creatinine level was increased gradually during last 3-4 months (from 1.2 mg/dl to 1.7 mg/dl). Her primary renal disease was unknown. She had been under the treatment of tacrolimus 2+1 mg, prednisolone 5 mg, mycophenolate sodium 3 × 360 mg. Physical examination was normal. Serum creatinine was 1.82 mg/dl, urine microscopy was normal. 154 mg/day proteinuria was obtained. ANA was positive, though ENA was negative. Anti CMV IgM was nega-

tive, whereas serum BK/JC PCR was positive. Serum tacrolimus level was 9.5 ng/ml. Transplant renal doppler ultrasonography revealed normal findings. Renal biopsy was performed. Intracellular inclusions, cytoplasmic and nuclear enlargement in tubular epithelial cells and tubular necrosis were seen on light microscopy. These biopsy findings might suggest viral infection of the renal allograft. Immunohistochemical analysis of the renal biopsy for CMV was negative, but study with SV40 antigen could not be performed as it was not available in our center. Intracellular spherical viral particles were seen in some tubular epithelial cells on EM (Fig. 1). Viral particles were in paracrystalline structure and about 30 nm in diameter. They were differentiated from inclusions of adenovirus with 80-100 nm in diameter (Fig. 2). Finally, BKVN was diagnosed.


BKVN is one of the well-known reasons of morbidity in renal transplant patients. It occurs with a prevalence of 1-10% in renal transplant patients and graft loss is up to 80%.<sup>3,4</sup> BKVN occurs mostly during the first year after transplantation and it is characterized only by deterioration of renal functions, usually without any symptoms.<sup>1</sup> Early diagnosis is important to prevent allograft dysfunction in kidney transplant patients. Our patient was also declared no symptoms, but only a gradual increase in serum creatinine was observed in the second year of follow up.



**Fig. 1** Tubular epithelial cell, intranuclear inclusions (10,000×).

The pathogenesis of BKVN is characterized by high grade BKV replication in renal-tubular epithelial cells of renal allograft. Necrosis of tubular cells let BKV leak into the tissue and blood, and then inflammatory cell infiltration to interstitium occurs. This leads to tubular atrophy, interstitial fibrosis and therefore impaired graft function. Intensive immunosuppressive therapy is the leading risk factor in the development of BKVN.<sup>4</sup>

Plasma and urine polymerase chain reaction (PCR), urine cytology, and urine electron microscopy (EM) can be performed in diagnosis of BKVN whereas renal biopsy is the gold standard method.<sup>3,5</sup> Multiple biopsy should be performed because of multi-focal involvement to prevent sampling errors and biopsy specimen should contain medullary parenchyma as the virus is more likely to present in the medulla.<sup>5</sup> Intranuclear inclusions, lysis or necrosis of tubular cells showing tubulointerstitial inflammation could be observed on light microscopy. However, changes observed during light microscopy are not pathognomonic for BKVN. Immunohistochemistry (SV40 staining) and EM should be performed.<sup>6</sup>



**Fig. 2** Intranuclear inclusions in higher magnification. Spherical viral particles with a diameter of 30 nm (60,000×).

Herpes simplex virus, adenovirus, CMV, Epstein-Barr virus (EBV) should also be considered in differential diagnosis as they may cause similar histologic findings. Immunohistochemistry and EM can be helpful in differential diagnosis.<sup>6-8</sup> Viral particles of BKV are characteristically 30–50 nm in diameter and occasionally form crystalloid structures, whereas inclusions due to family of herpesviridae (including Herpes simplex, EBV and CMV) and adenoviruses are bigger in size (120–150 nm and 70–90 nm respectively).<sup>2,6,9,10</sup>

In our patient, size of the viral particles was 30 nm in average. Although light microscopic detection of intranuclear inclusions suggested viral infection of renal allograft, it was the EM that defined dimensions of inclusions and helped the diagnosis. In conclusion, EM evaluation of allograft biopsy may be important in the differential diagnosis of different viral infections of allograft.

### Conflicts of interest

The authors declare that they have no conflicts of interest related to the contents of this article.

### BIBLIOGRAFÍA

1. van Aalderen MC, Heutinck KM, Huisman C, ten Berge IJ. BK virus infection in transplant recipients: clinical manifestations, treatment options and the immune response. *Neth J Med.* 2012;70(4):172–83.
2. Nicleleit V, Hirsch HH, Zeiler M, Gudat F, Prince O, Thiel G, Mihatsch MJ. BK-virus nephropathy in renal transplants-tubular necrosis, MHC-class II expression and rejection in a puzzling game. *Nephrol Dial Transplant.* 2000;15:324–32.
3. Hirscha HH, Randhawa P, the AST Infectious Diseases Community of Practice. BK polyomavirus in solid organ transplantation. *Am J Transplant.* 2013;13:179–88.
4. Sawinski D, Goral S. BK virus infection: an update on diagnosis and treatment. *Nephrol Dial Transplant.* 2015;30(2):209–17.
5. Nicleleit V, Hirsch HH, Binet IF, Gudat F, Prince O, Dalquen P, et al. Polyomavirus infection of renal allograft recipients: from latent infection to manifest disease. *J Am Soc Nephrol.* 1999;10:1080–9.
6. Dickersin GR. Renal glomerular disease and infectious agents. In: *Diagnostic electron microscopy.* 2nd ed. Springer; 2000. pp. 661 and 891.
7. Latif S, Zaman F, Veeramachaneni R, Jones L, Uribe-Urbe N, Turbat-Herrera EA, Herrera GA. BK polyomavirus in renal transplants: role of electron microscopy and immunostaining in detecting early infection. *Ultrastruct Pathol.* 2007;31(3):199–207.
8. Liptak P, Kemeny E, Ivanyi B. Primer: histopathology of polyomavirus-associated nephropathy in renal allografts. *Nat Clin Pract Nephrol.* 2006;2(11):631–6.
9. Hirsch HH, Brennan DC, Drachenberg CB, Ginevri F, Gordon J, Limaye AP, et al. Polyomavirus-associated nephropathy in renal transplantation: interdisciplinary analyses and recommendations. *Transplantation.* 2005;79(10):1277–86.
10. Cheville NF. Cytopathology in viral diseases. In: *Ultrastructural pathology: an introduction to interpretation.* 1st ed. Iowa State University Press; 1994. p. 502.

Simge Bardak<sup>a,\*</sup>, Kenan Turgutalp<sup>a</sup>, Ebru Ballı<sup>b</sup>,  
Banu Coşkun Yılmaz<sup>b</sup>, İclal Gürses<sup>c</sup>, Kaan Esen<sup>d</sup>,  
Serap Demir<sup>a</sup>, Ahmet Kiyıkım<sup>a</sup>

<sup>a</sup> Division of Nephrology, Department of Internal Medicine, School of Medicine, Mersin University, 33079 Mersin, Turkey

<sup>b</sup> Department of Histology and Embryology, School of Medicine, Mersin University, Turkey

<sup>c</sup> Department of Pathology, School of Medicine, Mersin University, Turkey

<sup>d</sup> Department of Radiology, School of Medicine, Mersin University, Turkey

\* Corresponding author.

E-mail address: [bardaksimge@gmail.com](mailto:bardaksimge@gmail.com) (S. Bardak).

0211-6995/© 2016 Sociedad Española de Nefrología. Published by Elsevier España, S.L.U. This is an open access article under the CC BY-NC-ND license (<http://creativecommons.org/licenses/by-nc-nd/4.0/>).  
<http://dx.doi.org/10.1016/j.nefro.2016.03.015>

## Factores de riesgo asociados a hernias en diálisis peritoneal

### Risk factors associated with hernias on peritoneal dialysis

Sr. Director:

El líquido de diálisis en la cavidad peritoneal aumenta la presión intraperitoneal (PIP)<sup>1</sup>. Este aumento de presión puede favorecer la aparición de complicaciones mecánicas de pared abdominal, en concreto, de las hernias. Además de poder contribuir al fallo de ultrafiltración y ser causa de salida de la técnica dialítica.

El objetivo del estudio fue valorar la frecuencia de hernias, objetivar los factores de riesgo para su desarrollo. Y ver si han supuesto fracaso de la técnica.

Estudiamos los pacientes prevalentes en diálisis peritoneal a 1 de agosto de 2015 en El Complejo Asistencial Universitario de León. Analizamos las variables: edad, sexo, modalidad, tiempo en diálisis, poliquistosis, antecedentes de cirugía abdominal, diagnóstico y reparación de hernia antes de iniciar diálisis, los parámetros antropométricos: índice de masa corporal (IMC), el índice de tejido adiposo (FTI) y el índice de tejido muscular (LTI) medidos por bioimpedancia, volumen diurno/sc, volumen nocturno/sc; el volumen residual, la PIP y la ultrafiltración medidos en un test de equilibrio peritoneal. Comparamos las variables entre el grupo con hernias y sin ellas. En el análisis estadístico las variables continuas se expresan en media y desviación típica, en caso de variables discretas se presentan las frecuencias absolutas y porcentajes. Se evalúa la asociación entre variables cualitativas con el test de Chi-cuadrado y entre variables cuantitativas mediante el test de la t de Student de 2 colas. En las comparaciones, las pruebas se consideran significativas cuando  $p < 0,05$ . Se usó el programa informático estadístico SPSS® para Windows.

Analizamos 44 pacientes, 27 varones (61,4%), 17 mujeres (38,6%), 28 en diálisis peritoneal continua ambulatoria (DPCA) (63,6%), el tiempo medio en diálisis  $27,63 \pm 19,1$  meses, 3 poliquísticos (6,8%), 22 tenían antecedentes de cirugía abdominal (50%) y 8 (18,8%) con hernia reparada previamente al inicio de diálisis.

Hubo 8 hernias (18,8%), 3 umbilicales y 5 inguinales, 7 en varones (87,5%), 50% en DPCA. En 6 pacientes se cambió la prescripción a diálisis peritoneal automatizada (DPA) con día seco, un paciente se mantuvo en DPCA con disminución del volumen/sc, con estos cambios de prescripción 6 (75%) pacientes permanecieron asintomáticos y sin complicaciones de incarceration ni estrangulación. Una hernia (12,5%) fue reparada quirúrgicamente con implante de malla, con paso temporal del paciente a hemodiálisis, debido a la presencia de dolor persistente.

No hubo diferencias entre los pacientes con hernias y sin hernias en las variables edad, modalidad, IMC, FTI, LTI, tiempo en diálisis, volumen/sc, ultrafiltración y la PIP. En cambio, hubo mayor volumen residual en los pacientes con hernias  $467 \pm 61,8$  frente a  $360,9 \pm 116$  ml ( $p 0,017$ ). Había más poliquísticos, más con hernias y cirugía abdominal previa en el grupo con hernias ( $p < 0,05$ ) (tabla 1). El 100% del grupo con hernias tenía  $PIP > 13$  cm/H<sub>2</sub>O.

Analizamos a los que tenían  $PIP > 13$  cm/H<sub>2</sub>O, fueron 34 pacientes y los comparamos con los que tenían PIP menor. El tiempo en diálisis fue de  $31,47 \pm 18$  vs.  $14,55 \pm 15$  meses ( $p 0,012$ ), el IMC  $27,68 \pm 4$  vs.  $21,62 \pm 46$  kg/m<sup>2</sup> ( $p 0,001$ ), el FTI  $13,6 \pm 5$  vs.  $7,6 \pm 4$  ( $p 0,02$ ), el volumen de infusión diurno/sc  $1.103,12 \pm 132$  vs.  $875 \pm 349$  ml/m<sup>2</sup> ( $p 0,003$ ) y el volumen residual  $411,11 \pm 94$  vs.  $275,14 \pm 125$  ml ( $p 0,001$ ). No encontramos diferencias en el resto de variables, incluida la ultrafiltración.

La frecuencia de hernias es variable entre el 12-37% en distintos estudios<sup>2</sup>, y similar a la encontrada en nuestra serie. Y no tienen por qué influir en la supervivencia de la técnica<sup>3</sup>. Ningún paciente ha tenido que abandonar la técnica hasta el momento, si bien, ha supuesto, en nuestra serie, la necesidad de aumentar el uso de cicladora con día seco.

Al igual que en otros estudios, ni la PIP ni el volumen de infusión parecen predecir la aparición de hernias abdominales<sup>1,4</sup>. Está descrita, en cambio, su relación posi-